

## Successful treatment of neurocysticercosis with albendazole desensitization

Anh P. Nguyen,<sup>1</sup> Wesley Hoffman,<sup>4</sup> Bennett H. Penn,<sup>5</sup> David Pham,<sup>6</sup> Suzanne S. Teuber<sup>2,3</sup>

### Abstract

**Background:** Neurocysticercosis is a growing public health problem in the United States. Albendazole is a mainstay of medical therapy for neurocysticercosis, and here we present a case of hypersensitivity to albendazole leading to life-threatening disease progression.

**Objective:** To report the first successful albendazole desensitization protocol.

**Methods:** An oral albendazole 12-step desensitization protocol was developed, starting with 0.001 mg and progressing at 15 minutes intervals. Dosage for each subsequent step was as follows: 0.003 mg, 0.01 mg, 0.03 mg, 0.1 mg, 0.3 mg, 1 mg, 3 mg, 10 mg, 30 mg, 100 mg, 300mg.

**Results:** The patient rapidly improved from a symptomatic standpoint, and repeat MRI showed a dramatic improvement in lesions.

**Conclusion:** This successful desensitization protocol to albendazole can be of value to other patients with history suggestive of IgE-mediated allergy needing treatment for parasitic infections.

**Key words:** Albendazole, Adverse drug reaction, Anti-parasite, Drug hypersensitivity, Desensitization, Orally, Neurocysticercosis

### Citation:

Nguyen, A. P., Hoffman, W., Penn, B. H., Pham, D., Teuber, S. S. (2024). Successful treatment of neurocysticercosis with albendazole desensitization. *Asian Pac J Allergy Immunol*, 42(2), 176-179. <https://doi.org/10.12932/ap-191020-0983>

### Corresponding author:

Anh P. Nguyen  
Pediatrics Department; Div Allergy/Clin Immunol/Rheum,  
2516 Stockton Blvd, Sacramento, CA, 95817  
E-mail: aphnguyen@ucdavis.edu

### Affiliations:

<sup>1</sup> Department of Pediatrics; Division of Allergy, Immunology and Rheumatology, University of California Davis, School of Medicine, Sacramento, CA, USA.

<sup>2</sup> Department of Internal Medicine; Division of Rheumatology, Allergy and Clinical Immunology, University of California Davis, School of Medicine, Sacramento, CA, USA.

<sup>3</sup> Veterans Affairs Northern California Healthcare System, Mather, CA, USA.

<sup>4</sup> University of Louisville Health – Jewish Hospital, Pharmacy, Louisville, KY, USA

<sup>5</sup> Department of Internal Medicine; Division of Infectious Diseases, University of California Davis, School of Medicine, Sacramento, CA, USA

<sup>6</sup> Department of Radiology, University of California Davis, School of Medicine, Sacramento, CA, USA

### Introduction

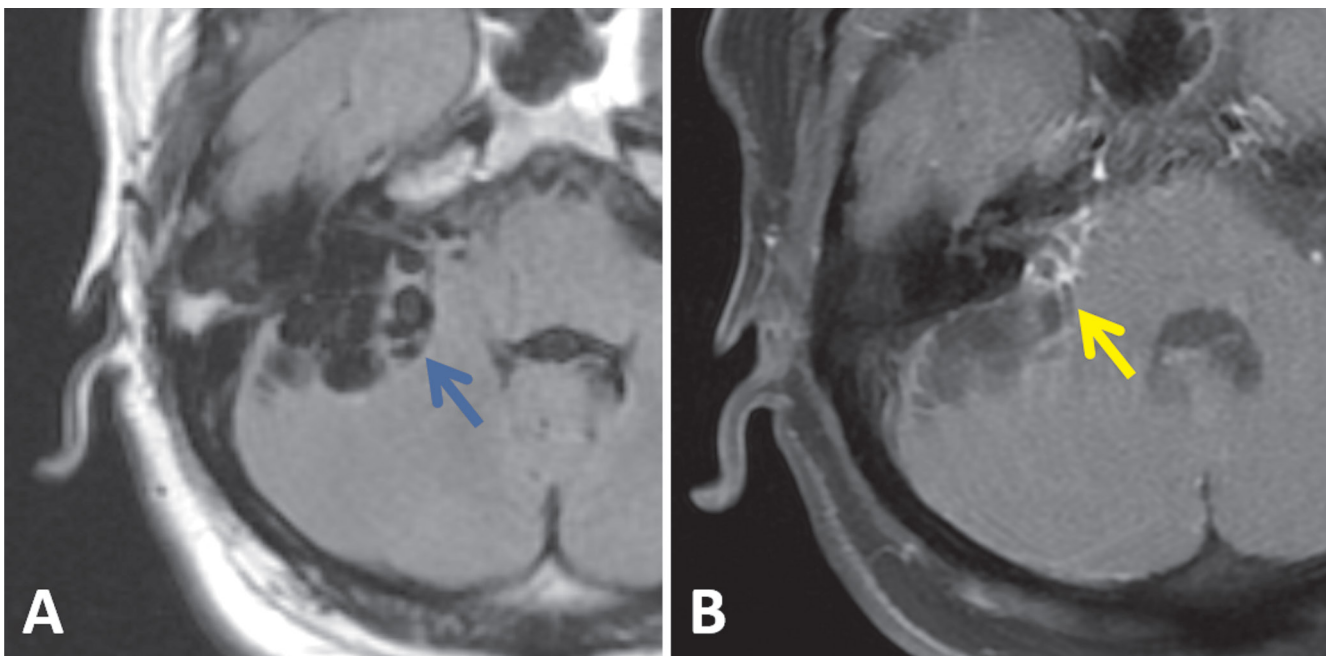
Neurocysticercosis (NCC) is the most common cause of preventable seizure, affecting millions of people worldwide, and can cause fatal infection.<sup>1</sup> Humans become infected after consuming undercooked food, particularly pork, contaminated by larvae of the cestode tapeworm *Taenia solium*. Left untreated, the larvae can survive inside the body for many years and migrate throughout the body where they encyst in skeletal muscle and various organs (cysticercosis). Larvae also have a tropism for the central nervous system, including brain parenchyma, ventricular system, spinal cord, and retina, and infection at this site results in NCC.<sup>1-2</sup> NCC can manifest in a variety of ways depending on the location and burden of infection. Cysts in brain parenchyma can cause mass effects, focal neurological defects, or seizures.

Ventricular system or subarachnoid cysts can cause cerebrovascular complications such as strokes and hemorrhage, and when they obstruct cerebral spinal fluid flow can cause hydrocephalus and herniation.<sup>1-2</sup>

Management of NCC varies with the location and number of viable cysticerci. Uncomplicated parenchymal cysts can often be treated with short courses of albendazole.<sup>1</sup> However, severe cases with a high burden of ventricular or subarachnoid cysts often require prolonged courses of therapy with albendazole in combination with antiparasitic drug praziquantel and corticosteroids for 6-12 months to prevent relapse.<sup>1</sup> Albendazole and praziquantel are typically well tolerated. Side effects may include mild nausea and headache, but rare hypersensitivity reactions have been reported including fixed drug reactions, contact urticaria and systemic reactions.<sup>3-6</sup> Here, we present a rare case of hypersensitivity to albendazole in a patient with severe subarachnoid and parenchymal NCC leading to self-discontinuation of therapy and life-threatening NCC disease progression. Since there are currently no effective cysticidal alternatives, we developed an albendazole desensitization protocol to ensure safe administration of albendazole for his NCC treatment.

## Report of Case

A 42-year-old man presented to the hospital for worsening of headaches, dizziness, seizures, and acute onset confusion. He was diagnosed with NCC a year prior and was initially treated as an inpatient with albendazole 400 mg (as two 200 mg tablets) twice per day and dexamethasone 4 mg intravenously three times per day for three days. He was then prescribed albendazole 200 mg with dexamethasone 8 mg orally twice daily to take as an outpatient for 21 days. He had no adverse reactions while in the hospital, but with the first dose of albendazole at home, he immediately developed lip itchiness and tingling, followed about one hour later by urticarial lesions on his face and back which resolved spontaneously. He repeatedly developed urticaria on his face and back or trunk one hour after each dose of albendazole, so he stopped taking it. There was no shortness of breath, wheezing, angioedema, gastrointestinal symptoms, or lightheadedness. He was not sure how many of the pills he eventually took. He subsequently was lost to follow-up for approximately one year, before re-presenting with worsening headaches and mental status changes. MRI of his brain showed increased cyst burden in the cerebellum and parietal lobes, with multicystic lesions extending into the quadrigeminal cistern, circum mesencephalic cisterns, and third ventricle resulting in obstructive hydrocephalus and leftward shift of the septum pellucidum (**Figure 1**).



**Figure 1.** Decrease of multicystic lesions shown by brain MRI images. (A) Pretreatment T2 FLAIR and (B) T1 postcontrast images at the level of the pons demonstrate multicystic lesions (blue arrow) with mild peripheral enhancement (yellow arrow) centered within the right anterior cerebellum and extending into the quadrigeminal space and into the cerebellopontine angle. Two months post-treatment (C) T2 FLAIR and (D) T1 postcontrast images demonstrate a significant decrease in size of the multicystic lesions (blue arrow) and absence of enhancement (yellow arrow).

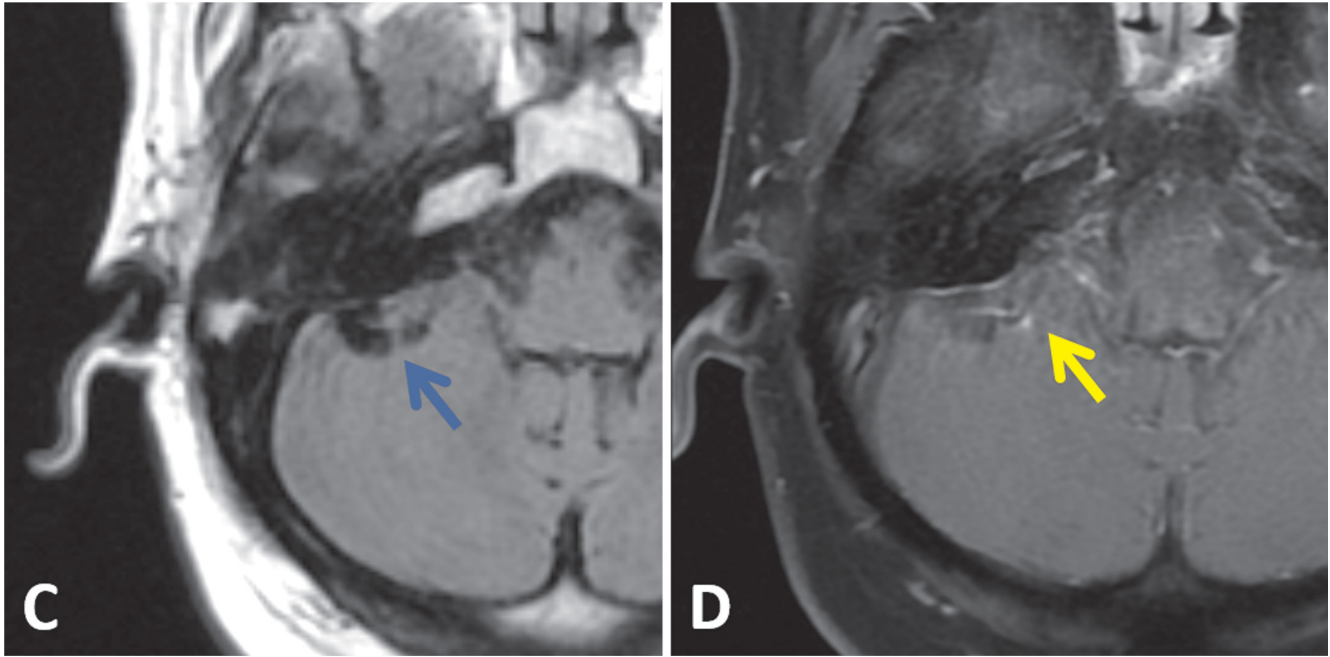


Figure 1. (Continued)

Based on the history, hypersensitivity to dexamethasone was ruled out as he had tolerated dexamethasone on its own previously after he had stopped albendazole. We elected not to perform skin testing since skin testing to albendazole is neither standardized nor validated. Given the patient's life-threatening neurological involvement and lack of alternative cysticidal drugs, an oral albendazole 12-step desensitization protocol was developed. We started with 0.001 mg and progressed at 15 minutes intervals. Dosage for each subsequent step was as follows: 0.003 mg, 0.01 mg, 0.03 mg, 0.1 mg, 0.3 mg, 1 mg, 3 mg, 10 mg, 30 mg, 100 mg, 300 mg (Table 1). He had no adverse reactions

Table 1. Albendazole Desensitization Protocol.

Step	Time (min)	Dilution (mg/mL)	Volume (ml)	Administered Dose (mg)	Cumulative Dose (mg)
1	15	0.004	0.25	0.001	0.001
2	30	0.004	0.75	0.003	0.004
3	45	0.004	2.5	0.01	0.014
4	60	0.004	7.5	0.03	0.044
5	75	0.04	2.5	0.1	0.144
6	90	0.04	7.5	0.3	0.444
7	105	0.4	2.5	1	1.444
8	120	0.4	7.5	3	4.444
9	135	4	2.5	10	14.444
10	150	4	7.5	30	44.444
11	165	40	2.5	100	144.444
12	180	40	7.5	300	444.444

during the protocol, nor during the remainder of his admission for 8 days prior to discharge on albendazole 400 mg three times daily, dexamethasone 8 mg twice per day, and praziquantel 1500 mg three times daily.

The patient rapidly improved from a symptomatic standpoint and repeat MRI 2 months later showed a dramatic improvement in lesions and degree of hydrocephalus (Figure 1). He has completed 12 months of combined therapy with albendazole and praziquantel therapy without recurrence of urticaria or NCC.

### Discussion

This report describes a rare case of hypersensitivity reaction to albendazole. Drug hypersensitivity reactions (DHRs) correspond to 10 to 15% of all adverse reactions.<sup>7</sup> DHRs can become a significant barrier in patients' treatment as demonstrated in our patient. Continued exposure of sensitized patients to a known allergenic substance induces systemic release of inflammatory mediators which can cause a range of adverse reactions from mild allergic reactions to life-threatening anaphylaxis. Avoidance of the offending drug, on the other hand, can lead to progression of disease and significant morbidity when no suitable alternative exists. Ventricular and subarachnoid NCC, as this patient had, is associated with a 50% mortality rate due to progressive hydrocephalous and herniation if antiparasitic agents are not used.<sup>8</sup> In these cases where alternative therapies are inferior or not available, drug desensitization can help deliver full therapeutic doses of drugs in an incremental fashion without eliciting systemic reactions. The progressive administration of the allergenic substances renders effector cells less reactive and induces a temporary state of drug tolerance. This modifies a patient's response to the drug temporarily and allows patients to safely receive the drug.<sup>7</sup>

There have been reported cases of DHRs to other anthelmintics, including praziquantel. Multiple reports of praziquantel desensitization protocols with use of premedication (steroids, antihistamines, H<sub>2</sub>-receptor antagonists, and leukotriene receptor antagonists) have been described.<sup>3</sup> In addition, other medications with azole moieties, such as the antifungal drug fluconazole, have been successfully used following desensitization, though the structures of 'azole' class antifungals are dramatically different from that of albendazole.<sup>9-10</sup> However, to date, there is no available albendazole desensitization protocol. We report the first case of successful albendazole desensitization, which can be of value to those patients with a history suggestive of IgE-mediated allergy needing treatment for life-threatening parasitic infections.

## References

1. White AC, Coyle CM, Rajshekhar V, Singh G, Hauser WA, Mohanty A, et al. Diagnosis and treatment of neurocysticercosis: 2017 Clinical Practice Guidelines by the Infectious Diseases Society of America (IDSA) and the American Society of Tropical Medicine and Hygiene (ASTMH). *Am J Trop Med Hyg.* 2018;98(4):945-66.
2. Garcia HH, Nash TE, Brutto OHD. Clinical symptoms, diagnosis, and treatment of neurocysticercosis. *Lancet Neurol.* 2014;13(12):1202-15.
3. Patel T, Lukawska J, Rowe J, Bailey RL. Treatment of schistosomiasis in a patient allergic to praziquantel: a desensitization and treatment protocol. *Am J Trop Med Hyg.* 2016;95(5):1041-3.
4. Gonzalez-Mendiola R, Martinez Borque N, Palomeque Rodriguez T, Torrecillas Toro M, Martinez Bohigas D. Type I allergic reaction to benzimidazole antihelminthics. *Allergy.* 2007;62:713-4.
5. Macedo NA, Pineyro MI, Carmona C. Contact urticaria and contact dermatitis from albendazole. *Contact Dermatitis.* 1991;25:73-5.
6. Mahboob A, Haroon TS. Fixed drug eruption with albendazole and its cross-sensitivity with metronidazole – a case report. *J Pak Med Assoc.* 1998;48:316-7.
7. Bonamichi-Santos R, Castells M. Diagnoses and management of drug hypersensitivity and anaphylaxis in cancer and chronic inflammatory diseases: reactions to taxanes and monoclonal antibodies. *Clin Rev Allergy Immunol.* 2018;54(3):375-85.
8. Sotelo J, Marin C. Hydrocephalus secondary to cysticercotic arachnoiditis. A long-term follow-up review of 92 cases. *J Neurosurg.* 1987;66(5):686-9.
9. Rankin B, Jariwala S. Graded challenge protocol for fluconazole hypersensitivity in a patient with cryptococcal pneumonitis. *Ann Allergy Asthma Immunol.* 2012;108(6):466.
10. Sheehan DJ, Hitchcock CA, Sibley CM. Current and emerging azole antifungal agents. *Clin Microbiol Rev.* 1999;12(1):40-79.