

# Predictive factors for invasive fungal rhinosinusitis in diabetic patients: Systematic review and data re-analysis

Thwe Phyoo Kan Nyunt,<sup>1,2</sup> Joaquim Mullol,<sup>3</sup> Kornkiat Snidvongs<sup>1,2</sup>

## Abstract

This systematic review aims to identify prognostic factors for the overall survival of invasive fungal rhinosinusitis (IFRS) in patients with diabetes using original data from the existing published articles. Systematic searches of Medline, EMBASE, and Cochrane Library databases were performed to include articles from 1988 to 2019 using the terms: “fung\*” AND “rhinosinusitis” AND “invasive” AND “diabetes OR ketoacidosis”. Data from 258 diabetic patients with IFRS (mean age 55.9 years, 55.6% male, 124 studies) were extracted for data analysis. The mortality rate was 31.8%. Seven variables: plasma glucose level, HbA1C, ketoacidosis, leukopenia, serum creatinine level, duration of diabetes, and the cavernous sinus extension were assessed. Univariate analysis was done for each variable and revealed that the cavernous sinus extension was a significant risk factor. Multivariable logistic regression analysis confirmed that the cavernous sinus extension independently predicted mortality in patients with diabetes (hazard ratio (HR) 2.6, 95% confidence interval (CI) 1.2 to 5.4,  $p = 0.01$ ). Kaplan Meier curve and Log-rank test were used for analyzing survival outcomes. The twelve-month overall survival rate of the patients with the cavernous sinus extension was 43.9% compared to 73.9% for the patients without the cavernous sinus extension ( $p = 0.01$ ). Appropriate treatment of this condition could enhance the survival outcomes.

**Key words:** rhinosinusitis, diabetic ketoacidosis, cavernous sinus, glycated haemoglobin A, creatinine, blood glucose, fungal

## From:

- <sup>1</sup> Department of Otolaryngology, Faculty of Medicine, Chulalongkorn University, Bangkok, Thailand
- <sup>2</sup> Endoscopic Nasal and Sinus Surgery Excellence Center, King Chulalongkorn Memorial Hospital, Bangkok, Thailand
- <sup>3</sup> Rhinology Unit & Smell Clinic, ENT Department, Hospital Clinic, Universitat de Barcelona, IDIBAPS, CIBERES. Barcelona, Catalonia, Spain

## Corresponding author:

Kornkiat Snidvongs  
Faculty of Medicine, Chulalongkorn University, Pathumwan,  
Bangkok 10330, Thailand  
E-mail: drkornkiat@yahoo.com

## Introduction

Invasive fungal rhinosinusitis (IFRS) is a fatal disease with a 50-80% mortality rate and serious complications.<sup>1</sup> The clinical presentations of IFRS which include headache, fever, facial swelling, facial pain, and symptoms of nearby structures invasion such as ophthalmoplegia and vision problems, are similar between the two most common fungi, aspergillosis and mucormycosis. Extensive tissue necrosis, angioinvasion, extensions into the orbit, intracranial complications and the cavernous sinus extension are common complications. The incidence of IFRS in diabetic patients is increasing along with the increasing prevalence of diabetes. The WHO announced that diabetes was the seventh leading cause of death in 2016.<sup>2</sup>

Early diagnosis, prompt treatment of the IFRS and restoration of the defective immune system are essential to improve the patient's survival. The relationship between diabetes

and prognosis of the IFRS is controversial. Hyperglycemia and acidosis in diabetic ketoacidosis (DKA) result in a rapid progression of IFRS and mortality.<sup>3</sup> However, a greater survival rate of IFRS in patients with diabetes mellitus compared to other immunosuppressive conditions was reported.<sup>4</sup> The diversity of treatment outcomes across studies is due to a great variety of the immune status among the diabetic patients in the studies. Multiple factors affecting the immune system include hyperglycemic state (high plasma glucose and HbA1C levels), ketoacidosis, polymorphonuclear cell function, duration of diabetes, diabetes with multiple organ impairments. To date, prognostic factors of IFRS in diabetic patients are not evident. This systematic review aims to identify the key prognostic factors which predict the overall survival of diabetic patients with IFRS using the pooled data from the existing published articles.

## Material and Methods

This systematic review followed the Preferred Reporting Items for Systematic reviews and Meta-Analyses (PRISMA) statement. Medline, EMBASE, and Cochrane database were searched using the terms: “fung\*” AND “rhinosinusitis” AND “invasive” AND “diabetes OR ketoacidosis”. The last search was performed on 30 May 2019. Inclusion criteria were case reports or case series reporting IFRS patients with original data regarding diabetic condition, the disease extension, medical and surgical treatments, and survival outcomes. Data reported by the same authors or the same institutions was checked to exclude any duplication. Articles were excluded when duplication was uncertain. Case series were excluded when the data of individual patients were not separately reported. Articles in a language other than English were excluded. Diagnostic criteria for diabetes mellitus were fasting plasma glucose values  $\geq 7.0$  mmol/L (126 mg/dl), a 2-hour post-load plasma glucose level  $\geq 11.1$  mmol/L (200 mg/dl), HbA1c  $\geq 6.5\%$  (48 mmol/mol); or a random plasma glucose  $\geq 11.1$  mmol/L (200 mg/dl) with the presence of signs and symptoms.<sup>5,6</sup> Diagnostic criteria for IFRS were radiological imaging and histopathological evidence of hyphal forms within the sinus mucosa, submucosa, blood vessels, or bone.<sup>7</sup>

Study selection was performed independently by two reviewers (TPKN and KS). The reviewers independently screened the titles and abstracts based on the predetermined eligibility criteria. The full texts of the selected articles were reviewed. Data were extracted from the included studies using a predetermined data collection spreadsheet. Six prognostic factors related to diabetes (plasma glucose level, HbA1C, ketoacidosis, leukopenia, blood creatinine level, and duration of diabetes,) and one prognostic factor related to IFRS extension (the cavernous sinus extension) were evaluated. The outcome was overall survival. Time to event was measured from the initial diagnosis of invasive fungal sinusitis to death. Univariate analysis was done for each variable. Variables with potential risks were incorporated to multivariate analysis. Backward stepwise Cox proportional hazard model was run to assess potential hazard ratio. Kaplan Meier curve and Log-rank test were used for analyzing survival outcomes. STATA 15 was used for the data analysis. A *p*-value less than 0.05 was considered statistically significant.

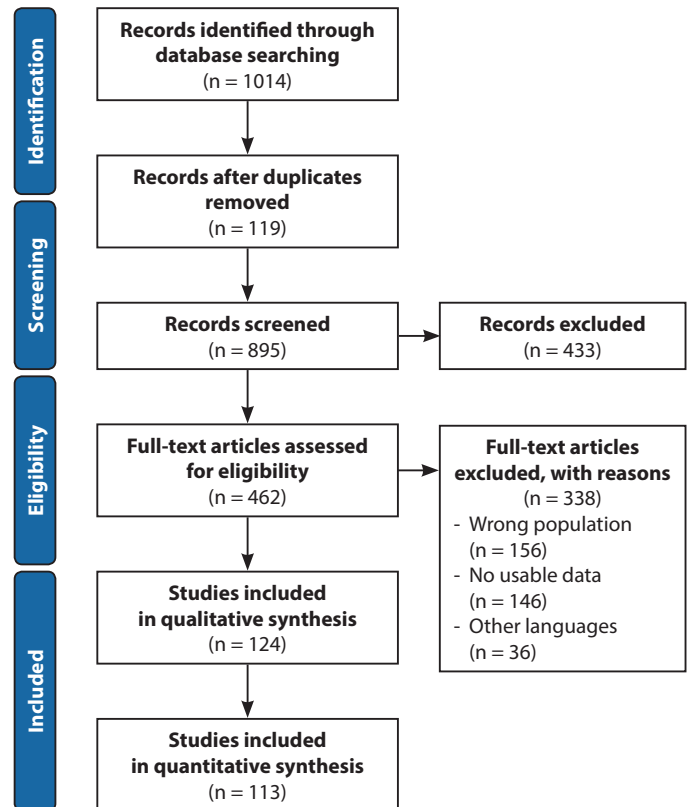
## Results

### Study selection

A total of 1,014 articles were identified by systematic searches. There were 119 duplicates. The titles and the abstracts of 895 studies were screened, 462 full texts were reviewed, and 338 studies were excluded after the full text review. The reasons for exclusion are listed in **Figure 1**. Finally, 124 studies were included for data synthesis.<sup>8-131</sup> A flow chart of the study retrieval and selection is presented in **Figure 1**.

### Patients

There were 258 diabetic patients with IFRS. The mean age was 55.9 years and 55.6% were male. There was a wide geographical distribution. Most patients were from India (17%), followed by USA (16%), Korea (14%), Iran (9%) Turkey (8%),



**Figure 1. Prisma flow diagram on the selected manuscripts for analysis**

Germany (3%), Taiwan (3%) and Japan (3%). Type II diabetes was 87.2% and type I was 12.8%. Thirteen patients (5.0%) were newly diagnosed with type II diabetes at the time of admission. Most patients (71.4%) had poor glycemic control. Fifty-one patients (19.8%) had diabetic ketoacidosis.

Mucormycosis accounted for 62.9% and aspergillosis accounted for 24.2% of the IFRS patients. Three patients (1.0%) had both mucormycosis and aspergillosis. Other types of fungi such as *Candida* species and *Absida corymbifera* accounted for 3.6%. The type of fungal hyphae was not specified in 8.6% of the patients. The mean duration of symptoms was  $22.7 \pm 37.6$  days. Two-hundred and forty-one patients (93.4%) were diagnosed with acute IFRS and 17 patients (6.7%) were chronic IFRS. The mean duration of symptoms in acute IFRS was  $12.7 \pm 15$  days and chronic IFRS was  $103 \pm 67$  days. Symptoms and signs were reported in 229 patients (118 records): 152 patients (66.4%) had complaints of eye symptoms and 77 patients (33.6%) had headaches. Black eschar was the most common sign. Fourteen patients (6.1%) did not have black mucosa or necrosis. Radiological imaging was reported in 245 patients (120 records), 129 patients (52.7%) had orbital invasion and 50 patients (20.4%) had the cavernous sinus invasion. The data from 120 records showed that 221 out of the 229 patients received antifungal treatment, 89% were treated with Amphotericin B derivatives (68% received Amphotericin B derivatives as a sole agent). Among patients who received Amphotericin B derivatives, 69% of the patients improved and survived. Eight patients did not receive antifungal treatment due to renal failure, multiorgan failure and severe medical

conditions. Of the total 258 patients, 221 patients (85.6%) underwent a surgical treatment, 165 patients (63.9%) underwent endoscopic approach.

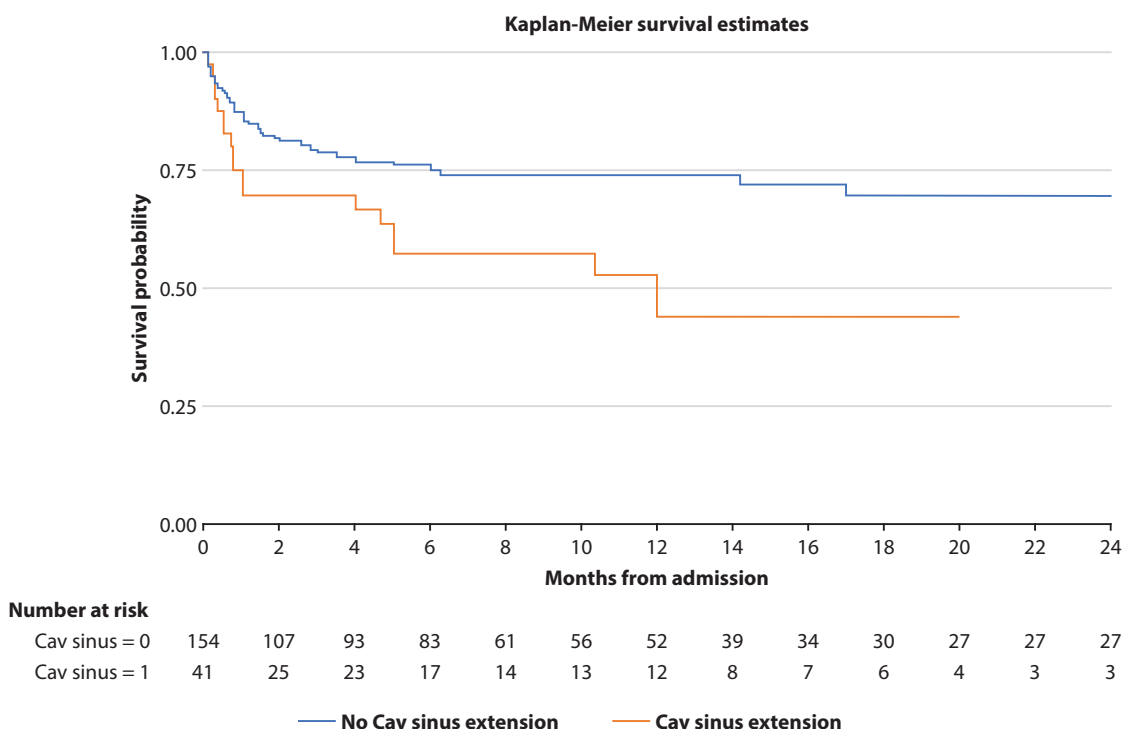
**Prognostic factors and overall survival analysis**

Follow-up time was reported in 207 patients (120 records). The data were used for overall survival analysis. The mortality rate was 31.8%. The mean follow-up time was 11.4 ± 18.0 months (range 0.6-120 months). Plasma glucose levels were reported in 70 patients (52 records). The mean plasma glucose level was 391.3 ± 216.4 mg/dl and 56 patients (80%) had plasma glucose above 200 mg/dl. HbA1c levels were reported in 32 patients (21 records). The mean HbA1c was 9.7 ± 2.8 and 10 patients (32%) had HbA1c greater than 11. The duration of having diabetes before admission was reported in 56 patients

(44 records). The mean duration of having diabetes was 5.6 ± 6.2 years. Nineteen patients (33%) had less than one-year duration, 21 (38%) between 1-10 years and 16 (29%) above ten years. White blood cell counts were reported in 55 patients (42 records). The mean total white blood cell count was 13,576.0 ± 8,846.5 × 10<sup>3</sup> cell per liter. Six patients (10%) had a total white blood cell count less than 4,000 cell per liter, 18 (33%) had 4,000-11,000 and 31 (57%) had greater than 11,000. Serum creatinine was reported in 35 patients (24 records). The mean serum creatinine level was 1.5 ± 0.8 mg/dl. Twenty-eight patients (79%) had serum creatinine level greater than 1 mg/dl. Fifty-one patients (24.6%) had ketoacidosis. Radiological imaging was reported in 245 patients (120 records). Fifty patients (20%) had the cavernous sinus extension.

**Table 1. Prognostic factors on overall survival of invasive fungal rhinosinusitis in diabetic patients**

Risk factors	Univariate analysis				Multivariate analysis		
	Hazard ratio	95% Confidence Interval	P-value	Hazard ratio	95% Confidence Interval	p-value	
Age	1.00	0.98 - 1.01	0.86	1.00	0.98 - 1.02	0.76	
Diabetes ketoacidosis	0.68	0.39 - 1.17	0.16	1.57	0.72 - 3.43	0.26	
Cavernous sinus involvement	2.09	1.2 - 3.6	0.01	2.56	1.21 - 5.40	0.01	
Plasma Glucose	2.05	0.61 - 6.96	0.25				
HbA1C	0.38	0.05 - 3.14	0.37				
Total WBC count	1.22	0.55 - 2.72	0.62				
Creatinine	1.68	0.20 - 14.01	0.63				
Duration of DM	1.07	0.56 - 2.04	0.63				



**Figure 2. Overall survival of diabetic patients with invasive fungal rhinosinusitis with and without the cavernous sinus extension**

The univariable logistic regression analysis revealed that the cavernous sinus extension was a significant risk factor (hazard ratio (HR) 2.1, 95% confidence interval (CI) 1.2 to 3.6,  $p = 0.01$ ). As a potential risk factor, diabetic ketoacidosis was assessed using multivariate analysis together with the cavernous sinus extension. The multivariable logistic regression analysis showed that the cavernous sinus extension independently predicted poor prognosis (HR 2.6, 95% CI 1.2 to 5.4,  $p = 0.01$ ). The data are displayed in **Table 1**. In the patients with the cavernous sinus extension, the overall survival at two months, six months and 12 months was 69.7%, 57.1%, and 43.9%, respectively. These overall survivals were significantly lower than those of the patients without the cavernous sinus extension (80.9%, 75.1% and 73.9%, respectively,  $p = 0.01$ ). The data are displayed in **Figure 2**.

## Discussion

In this review, the mortality rate of IFRS in diabetic patients was 31.8% which was lower than the mortality rate of IFRS in the general population (50-80 %).<sup>1,132,133</sup> In line with our review, a systematic review by Turner, et al. showed that IFRS in patients with diabetes had twice the overall survival than patients with other underlying diseases.<sup>133</sup>

Mucormycosis accounted for 62.9% in this systematic review. Invasive fungal rhinosinusitis in patients with diabetic ketoacidosis is mainly mucor infection rather than aspergillus infection because diabetic patients have excess iron available in the tissues and Mucors can use the excess iron to grow and spread. In addition, diabetes patients have reduced defensive cells such as neutrophils and macrophages and reduced chemotaxis and phagocytosis of the host.<sup>56</sup>

When the raw data of individual case reports were pooled, our findings showed that the cavernous sinus extension was an independent factor which predicted the overall survival of diabetic patients with IFRS. Angioinvasion and vascular thrombosis caused by IFRS lead to the cavernous sinus extension. A basic research by Frater et al.<sup>135</sup> assessed histologic features of disease and the fungal morphology in 20 patients with zygomycosis. Hyphal invasion of arterial and venous walls was seen in angioinvasion (100%), and prominent infarcts (94%). Additionally, prominent perineural invasion (90%) was present in most patients. Clinical presentations of cavernous sinus extension may include bilateral exophthalmos, complete ophthalmoplegia, lid drop, and signs of meningeal irritation associated with spiking fevers.<sup>134</sup> Similar to the cavernous sinus thrombosis in acute bacterial rhinosinusitis, our review showed that the cavernous sinus extension by IFRS was fatal.

The cavernous sinus is a dangerous area for endoscopic sinus and skull base surgeries due to its neurovascular structures. Therefore, the cavernous sinus extension is a hard-to-treat condition.

Although other variables also have potential risks, they are correctable resulting in more favorable outcomes. Understanding immunopathology of the underlying immunocompromised diseases and restoration of the host immune dysfunction are essential for treating IFRS together with adequate

surgery and appropriate antifungal treatments. Diabetes Mellitus affects both the humoral and cellular immune responses of the innate and adaptive immune systems. The expression of class I major histocompatibility complex is impaired. The structure of complement and the balance between complement activation and restriction are altered. In poorly controlled diabetes, hyperglycemia diminishes vascular dilation and activates protein kinase C which inhibits polymorphonuclear cells production, neutrophil migration, chemotaxis and phagocytic activity.<sup>136</sup> Furthermore, diabetic ketoacidosis causes an overexpression of the glucose-induced glucose-regulated protein (GRP) 78 which induces endothelial cell damage and fungal invasion.<sup>137</sup> In addition, when acidosis is present, iron is released from its binding proteins which regulates endothelial cell damage.<sup>138</sup> Iron and the overexpression of glucose-induced GRP78 enhance endothelial cell susceptibility to *R. oryzae*-induced fungal invasion leading to endothelial damage.<sup>136</sup> Germination and rapid filamentous growth of mucormycosis within the endothelial damage, the exposed basement membrane and extracellular matrix proteins cause angioinvasion, vessel thrombosis, and necrosis.<sup>139</sup>

IFRS is a fatal disease, therefore, neurological examination together with radiological imaging investigation should be performed to evaluate the cavernous sinus and intracranial extension. Magnetic resonance venography may be requested in specific cases for the assessment of the cavernous sinus extension. Diabetic ketoacidosis and hyperglycemic state should be assessed and treated.

The limitations of this systematic review included a retrospective nature of the included studies, and publication bias. Disadvantages of case reports and case series included missing data, confounders, and risks of bias. There were multiple factors which contributed to publication bias. Investigators commonly avoided submitting the results which were not supported by the known findings. Poor therapeutic outcomes and high mortality rate were not reported probably due to the investigators' assumption that they had made mistakes. On the other hand, publishers are not interested in the null results. In addition, most journals prefer high quality studies. Preregistered studies prior to data collection and analysis are preferred by several journals. Thus, a limited number of studies could be included.

## Conclusion

Therapeutic outcomes of invasive fungal rhinosinusitis in diabetic patients are diverse. The disease extension into the cavernous sinus predicts a high mortality rate. In practice, restoration of the immune function and a total disease eradication could improve the treatment outcomes. Patients can have favorable overall survival when diabetic conditions are well controlled.

## Acknowledgement

The authors would like to acknowledge Professor Maung Maung Khaing for his technical advice.

## Conflict of Interest

- Joaquim Mullol is or has been member of the advisory boards for GSK, Meda-Mylan Pharma, MSD, Novartis, SANOFI-Regeneron, AstraZeneca, and URIACH. He received Honoraria for speaking at symposia from GSK, SANOFI-Regeneron, Menarini, Meda-Mylan Pharma, MSD, URIACH, UCB, and Novartis. He received grants for research projects and clinical trials from MEDA-Mylan, SANOFI-Regeneron, GSK, Roche-Novartis, and URIACH.
- Kornkiat Snidvongs received Honoraria for speaking at symposia from Merck Sharp & Dohme, and Menarini
- Thwe Phyo Kan Nyunt has no conflict of interest.

## Authors contribution

- Thwe Phyo Kan Nyunt: literature search, study selection, data collection, drafting the article, and final approval
- Joaquim Mullol: expert opinion, revising the article, and final approval
- Kornkiat Snidvongs: conception, literature search, data collection, drafting the article, and final approval

## References

- Gillespie MB, O'Malley, Bert W Jr, Francis HW. An Approach to Fulminant Invasive Fungal Rhinosinusitis in the Immunocompromised Host. *Arch Otolaryngol Head Neck Surg.* 1998;124(5):520-6.
- World Health Organization [Internet]. Geneva: WHO; c2020 [cited 2020 Jun 8]. Diabetes; [about 5 screens]. Available from: <https://www.who.int/news-room/fact-sheets/detail/diabetes>
- Jung SH, Kim SW, Park CS, Song CE, Cho JH, Lee JH, et al. Rhinocerebral Mucormycosis: consideration of prognostic factors and treatment modality. *Auris Nasus Larynx.* 2009;36(3):274-9.
- Saedi B, Sadeghi M, Seilani P. Endoscopic management of rhinocerebral mucormycosis with topical and intravenous amphotericin B. *J Laryngol Otol.* 2011;125(8):807-10.
- American Diabetes A. Diagnosis and classification of diabetes mellitus. *Diabetes Care.* 2010;33 Suppl 1(Suppl 1):S62-9.
- Mathers CD, Loncar D. Projections of global mortality and burden of disease from 2002 to 2030. *PLoS Med.* 2006;3(11):e442
- deShazo RD, O'Brien M, Chapin K, Soto-Aguilar M, Gardner L, Swain R. A new classification and diagnostic criteria for invasive fungal sinusitis. *Arch Otolaryngol Head Neck Surg.* 1997;123(11):1181-8.
- Afroze SN, Korlepara R, Rao GV, Madala J. Mucormycosis in a Diabetic Patient: A Case Report with an Insight into Its Pathophysiology. *Contemp Clin Dent.* 2017;8(4):662-6.
- Al-Ajam MR, Bizri AR, Mokhbat J, Weedon J, Lutwick L. Mucormycosis in the Eastern Mediterranean: A seasonal disease. *Epidemiol Infect.* 2006;134(2):341-6.
- Alleyne CH Jr, Vishteh AG, Spetzler RE, Detwiler PW. Long-term survival of a patient with invasive cranial base rhinocerebral mucormycosis treated with combined endovascular, surgical, and medical therapies: case report. *Neurosurgery.* 1999;45(6):1461-4.
- Alsuhaibani A, Al-Thubaiti G, Al Badr F. Optic nerve thickening and infarction as the first evidence of orbital involvement with mucormycosis. *Middle East Afr J Ophthalmol.* 2012;19(3):340-2.
- Anders UM, Taylor EJ, Martel JR, Martel JB. Acute orbital apex syndrome and rhino-orbito-cerebral mucormycosis. *Int Med Case Rep J.* 2015;8:93-6.
- Arakawa H, Suto C, Notani H, Ishida T, Abe K, Ookubo Y. Selection of the antifungal agent decides prognosis of invasive aspergillosis: Case report of a successful outcome with voriconazole. *Int Ophthalmol.* 2014;34(1):85-9.
- Arndt S, Aschendorff A, Echternach M, Daemmrich TD, Maier W. Rhino-orbital-cerebral mucormycosis and aspergillosis: Differential diagnosis and treatment. *Eur Arch Otorhinolaryngol.* 2009;266(1):71-6.
- Arora V, Nagarkar NM, Dass A, Malhotra A. Invasive Rhino-Orbital Aspergillosis. *Indian J Otolaryngol.* 2011;63(4):325-9.
- Baban TA, Raad RA, Dandachi D, Kanj SS, Kanafani ZA. Three cases of mucormycosis from the middle east: Different risk factors leading to different outcomes. *Journal of Invasive Fungal Infections.* 2011;5(4):118-22.
- Bakhshae M, Bojdi A, Allahyari A, Majidi MR, Tavakol S, Najafzadeh MJ, et al. Acute invasive fungal rhinosinusitis: our experience with 18 cases. *Eur Arch Oto-Rhino-L.* 2016;273(12):4281-7.
- Bakshi SS. An unusual cause for facial nerve palsy: mucormycosis. *Int J Diabetes Dev C.* 2016;36(4):385-8.
- Balasubramaniam P, Madakira PB, Ninan A, Swaminathan A. Response of central nervous system aspergillosis to voriconazole. *Neurol India.* 2007;55(3):301-3.
- Busaba NY, Colden DG, Faquin WC, Salman SD. Chronic invasive fungal sinusitis: A report of two atypical cases. *Ear Nose Throat J.* 2002;81(7):462-6.
- Cabot RC, Scully RE, Mark EJ, McNeely BU, Diamond RD, Proppe KH. Case 38-1982: A 66-Year-Old Diabetic Woman with Sinusitis and Cranial Nerve Abnormalities. *N Engl J Med.* 1982;307(13):806-14.
- Çağatay AA, Öncü SS, Çalangu SS, Yildirmak TT, Özsüt HH, Eraksoy HH. Rhinocerebral mucormycosis treated with 32 gram liposomal amphotericin B and incomplete surgery: A care report. *BMC Infect Dis.* 2001;(1):22.
- Castillo L, Hofman V, Bétis F, Piche M, Roger PM, Santini J, et al. Longterm survival in acute rhinocerebral mucormycosis with giant cell arteritis and foreign body granulomas. *Pathol Res Pract.* 2001;197(3):199-203.
- Chan JCW, Yu DKH, Lee DLY, Abdullah VJ, Li KKW. Combined lateral orbitotomy and endoscopic transnasal orbital decompression in a case of orbital aspergillosis with impending intracranial invasion. *Case Rep Ophthalmol.* 2012;3(3):418-23.
- Chander J, Kaur J, Gulati N, Arora V, Nagarkar N, Sood S, et al. Sudden vision loss caused by rhino-orbital zygomycosis in diabetic patients: case series. *Mycoses.* 2011;54(4):e228-32.
- Chavez JA, Brat DJ, Hunter SB, Vega JV, Guarner J. Practical diagnostic approach to the presence of hyphae in neuropathology specimens with three illustrative cases. *Am J Clin Pathol.* 2018;149(2):98-104.
- Chi T-H, Chen H-S, Yuan C-H, Su F-M. Acute fulminant invasive fungal sinusitis with cavernous sinus syndrome. *JCPSP.* 2014;24 Suppl 3(9606447):S240-2.
- Chitsaz S, Bagheri J, Mandegar MH, Rayatzadeh H, Razavi J, Azadi L. Extensive Sino-Orbital Zygomycosis After Heart Transplantation: A Case Report. *Transplant Proc.* 2009;41(7):2927-9.
- Cho HJ, Jang MS, Hong SD, Chung SK, Kim HY, Dhong HJ. Prognostic factors for survival in patients with acute invasive fungal rhinosinusitis. *Am J Rhinol Allergy.* 2015;29(1):48-53.
- Choi HS, Choi JY, Yoon JS, Kim SJ, Lee SY. Clinical characteristics and prognosis of orbital invasive aspergillosis. *Ophthal Plast Reconstr.* 2008;24(6):454-9.
- Chua JLL, Cullen JF. Fungal pan-sinusitis with severe visual loss in uncontrolled diabetes. *Ann Acad Med Singap.* 2008;37(11):964-7.
- Chun HM, Skelton SC, Armstrong AW. Paranasal mucormycosis in a patient with AIDS presenting as a palatal mass. *Infect Dis Clin Pract.* 2006;14(4):235-8.
- Çolak AY, Gökçay F, Çelebisoy N, Gökçay A, Güler A, Pullukçu H, et al. Ophthalmoplegia due to invasive fungal sinusitis: A report of three cases. *Türk Noroloji Dergisi.* 2017;23(4):225-8.
- Cunha MA, Nery AF, Lima FP, Diniz Junior J, Maciel Neto J, Calado NB, et al. Rhinocerebral zygomycosis in a diabetic patient. *Rev Soc Bras Med Tro.* 2011;44(2):257-9.
- Dhirawani R, Asrani S, Pathak S, Sharma A. Facial translocation approach for management of invasive sinonasal aspergillosis. *J Oral Maxillofac Surg.* 2015;14(Suppl 1):482-7.
- Di Carlo P, Pirrello R, Guadagnino G, Richiusa P, Lo Casto A, Sarno C, et al. Multimodal surgical and medical treatment for extensive rhinocerebral mucormycosis in an elderly diabetic patient: A case report and literature review. *Case Rep Med.* 2014;527062.
- Di Coste A, Costantino F, Tarani L, Savastano V, Di Biasi C, Schiavi L, et al. Rhinocerebral zygomycosis with pansinusitis in a 14-year-old girl with type 1 diabetes: A case report and review of the literature. *Ital J Pediatr.* 2013;39(1).

38. Dinowitz M, Leen JS, Hameed M, Wolansky L, Frohman L. Sudden painless visual loss. *Surv Ophthalmol.* 2001;46(2):143-8.
39. Erami M, Shams-Ghahfarokhi M, Jahanshahi Z, Sharif A, Razzaghi -Abyaneh M. Rhinocerebral mucormycosis due to *Rhizopus oryzae* in a diabetic patient: A case report. *J Mycol Med.* 2013;23(2):123-9.
40. Escamilla Carpintero Y, Espasa Soley M, Bella Cueto MR, Prenafeta Moreno M. Sphenoid sinusitis with intracranial extension produced by an emergent fungus. *Acta Otorrinolaringol Esp.* 2011;62(2):158-60.
41. Fu KA, Nguyen PL, Sanossian N. Basilar artery territory stroke secondary to invasive fungal sphenoid sinusitis: A case report and review of the literature. *Case Rep Neurol.* 2015;7(1):51-8.
42. Giglio M, Caggiano G, De Blasi R, Brienza N, Bucaria V, Ladisa P, et al. A fatal rhino-cerebral zygomycosis in a young woman with latent diabetes mellitus and cerebral blood vessel agenesis. *Med Mycol J.* 2010;48(2):394-7.
43. Gupta R, Gupta B, Bal A, Gupta AK. Sinonasal mucormycosis with fungal ball: A rare case report. *Clin Rhinol.* 2014;7(2):64-6.
44. Gutiérrez-Delgado EM, Treviño-González JL, Montemayor-Alatorre A, Ceceñas-Falcón LA, Ruiz-Holguín E, Andrade-Vázquez CJ, et al. Chronic rhino-orbito-cerebral mucormycosis: A case report and review of the literature. *Ann Med.* 2016;6:87-91.
45. Hadzri MH, Azarisman SM, Fauzi ARM, Kahairi A. Invasive rhinocerebral mucormycosis with orbital extension in poorly-controlled diabetes mellitus. *Singapore Med J.* 2009;50(3):e107-e9.
46. Hendrickson RG, Olshaker J, Duckett O. Rhinocerebral mucormycosis: A case of a rare, but deadly disease. *J Emerg Med.* 1999;17(4):641-5.
47. Hoenigl M, Aspeck E, Valentin T, Heiling B, Seeber K, Krause R, et al. Sinusitis and frontal brain abscess in a diabetic patient caused by the basidiomycete *Schizophyllum commune*: Case report and review of the literature. *Mycoses.* 2013;56(3):389-93.
48. Horowitz A, Spindel D, Kraut R, Orentlicher G. Cavernous sinus thrombosis as a result of a fungal infection: A case report. *J Oral Maxillofac Surg.* 2013;71(11):1899.e1-e5.
49. Hosseini SMS, Borghei P. Rhinocerebral mucormycosis: Pathways of spread. *Eur Arch Otorhinolaryngol.* 2005;262(11):932-8.
50. Huang JS, Kok SH, Lee JJ, Hsu WY, Chiang CP, Kuo YS. Extensive maxillary sequestration resulting from mucormycosis. *Brit J Oral Max Surg.* 2005;43(6):532-4.
51. Huang Y, Gui L. Cavernous sinus-orbital apex aspergillus infection in a diabetic patient: A case report. *Medicine.* 2019;98(13):e15041.
52. Islam MN, Cohen DM, Celestina LJ, Ojha J, Claudio R, Bhattacharyya IB. Rhinocerebral zygomycosis: an increasingly frequent challenge: update and favorable outcomes in two cases. *Oral Surg Oral Med Oral Pathol Oral Radiol Endod.* 2007;104(5):e28-34.
53. Jacob NB, Chaney S. Rhino Orbito Cerebral Mucormycosis: A Fatal Acute Invasive Fungal Infection in Uncontrolled Diabetes. *Jnp-J Nurse Pract.* 2016;12(10):667-74.
54. Javadzadeh Bolouri A, Delavarian Z, Dalirsani Z, Tonkaboni A. Rhinocerebral mucormycosis in a diabetic patient with cranial nerve involvement. *Pak J Med Sci.* 2011;27(4):911-4.
55. Jhuo SJ, Wang WS, Kuo JY. Successful treatment of Aspergillus sinusitis with oral voriconazole: A case report. *J Intern Med Taiwan.* 2011;22(1):63-8.
56. Jung S-H, Kim SW, Park CS, Song CE, Cho JH, Lee JH, et al. Rhinocerebral Mucormycosis: Consideration of prognostic factors and treatment modality. *Auris Nasus Larynx.* 2009;36(3):274-9.
57. Karakurum B, Karatas M, Cagici AC, Uncu H, Yildirim T, Hurcan C, et al. Mucormycosis presenting with painful ophthalmoplegia. *Acta Neurol Belg.* 2005;105(4):201-5.
58. Kasapoglu F, Coskun H, Ozmen OA, Akalin H, Ener B. Acute invasive fungal rhinosinusitis: Evaluation of 26 patients treated with endonasal or open surgical procedures. *Otolaryng Head Neck.* 2010;143(5):614-20.
59. Kawakami H, Mochizuki K, Ishida K, Ohkusu K. Seven cases of localized invasive sino-orbital aspergillosis. *Jpn J Ophthalmol.* 2017;61(2):179-88.
60. Kazak E, Aslan E, Akalin H, Saraydarolu O, Hakyemez B, Erişen L, et al. A mucormycosis case treated with a combination of caspofungin and amphotericin B. *J Mycol Med.* 2013;23(3):179-84.
61. Kim E, Kim JY, Cho JH, Kang C. Image features of aspergillosis arising from the pterygopalatine fossa: A case report and literature review. *Oral Radiol.* 2014;30(2):192-5.
62. Kim ST, Kim WS, Lee HH, Kim JY. Successful treatment of invasive rhinopulmonary mucormycosis with an indolent presentation by combined medical and surgical therapy. *J Craniofac Surg.* 2013;24(2):e182-e4.
63. Knipping S, Holzhausen HJ, Koesling S, Bloching M. Invasive aspergillosis of the paranasal sinuses and the skull base. *Eur Arch Otorhinolaryngol.* 2007;264(10):1163-9.
64. Koc Z, Koc F, Yerdelen D, Ozdogu H. Rhino-orbital-cerebral mucormycosis with different cerebral involvements: Infarct, hemorrhage, and ophthalmoplegia. *Int J Neurosci.* 2007;117(12):1677-90.
65. Kofferidis DP, Karabekios S, Panagiotides JG, Bizakis J, Kyrmizakis D, Saridaki Z, et al. Successful treatment of rhinocerebral mucormycosis with liposomal amphotericin B and surgery in two diabetic patients with renal dysfunction. *J Chemother.* 2003;15(3):282-6.
66. Kok J, Gilroy N, Halliday C, Lee OC, Novakovic D, Kevin P, et al. Early use of posaconazole in the successful treatment of rhino-orbital mucormycosis caused by *Rhizopus oryzae*. *J Infect.* 2007;55(3):e33-e6.
67. Kulendra K, Habibi M, Butler C, Clarke P, Howard D. Use of posaconazole in the treatment of infective rhinocerebral mucormycosis. *J Laryngol Otol.* 2010;124(12):1314-7.
68. Lee DH, Yoon TM, Lee JK, Joo YE, Park KH, Lim SC. Invasive fungal sinusitis of the sphenoid sinus. *Clin Exp Otorhinolaryngol.* 2014;7(3):181-7.
69. Li CH, Lay CJ, Ho YH, Wang LS, Wang CL, Tsai CC. Successful treatment of two cases of invasive aspergillus sinusitis with voriconazole. *Tzu Chi Med. J.* 2010;22(2):106-10.
70. Li DM, Shang PP, Zhu L, De Hoog GS. Rhino-orbital-cerebral mycosis and cavernous thrombosis. *Eur J Inflamm.* 2014;12(1):1-10.
71. Mahomed S, Basanth S, Mlisana K. The successful use of amphotericin B followed by oral posaconazole in a rare case of invasive fungal sinusitis caused by co-infection with mucormycosis and aspergillus. *IDCases.* 2015;2(4):116-7.
72. Mane RS, Patil BC, Mohite AA. Rhinocerebral mucormycosis presenting as oroantral fistula. *Clin Rhinol* 2012;5(3):135-7.
73. Mathuram AJ, Mohanraj P, Mathews MS. Rhino-orbital-cerebral infection by *Syncephalastrum racemosum*. *J Assoc Physicians India* 2013;61(5):339-40.
74. Meas T, Mouly S, Kania R, Hervé D, Herman P, Kévorkian JP, et al. Zygomycosis: an uncommon cause for peripheral facial palsy in diabetes. *Diabetes Metab.* 2007;33(3):227-9.
75. Mimouni O, Curto CL, Danvin JB, Thomassin JM, Dessi P. Sinonasal mucormycosis: Case report. *Eur Ann Otorhinolaryngol Head Neck Dis.* 2010;127(1):27-9.
76. Mohamed MS, Abdel-Motaleb HY, Mobarak FA. Management of rhino-orbital mucormycosis. *Saudi Med J.* 2015;36(7):865-8.
77. Mohammadi R, Meidani M, Mostafavizadeh K, Iraj B, Hamedani P, Sayedain SMA, et al. Case series of rhinocerebral mucormycosis occurring in diabetic patients. *Caspian J Intern Med.* 2015;6(4):243-6.
78. Mok MMY, Fang BXH, Choy BY, Chan TM. Invasive fungal rhinosinusitis presenting as Bell's palsy in a kidney and liver transplant recipient. *J Formos Med Assoc.* 2017;116(11):910-1.
79. Mondy KE, Haughey B, Custer PL, Wippold FJ, Ritchie DJ, Mundy LM. Rhinocerebral mucormycosis in the era of lipid-based amphotericin B: Case report and literature review. *Pharmacotherapy.* 2002;22(4):519-26.
80. Morgand M, Rammaert B, Poirée S, Bougnoux ME, Tran H, Kania R, et al. Chronic invasive Aspergillus sinusitis and otitis with meningeal extension successfully treated with voriconazole. *Antimicrob Agents Chemother.* 2015;59(12):7857-61.
81. Moses AE, Rahav G, Barenholz Y, Elidan J, Azaz B, Gillis S, et al. Rhinocerebral mucormycosis treated with amphotericin B colloidal dispersion in three patients. *Clin Infect Dis.* 1998;26(6):1430-3.
82. Mundra RK, Gupta Y. Mucormycosis of nose and paranasal sinuses with orbital complication in young diabetic. *Indian J Otolaryngol Head Neck Surg.* 2008;60(4):360-4.
83. Narayanan S, Panarkandy G, Subramanian G, Radhakrishnan C, Thulaseedharan NK, Manikath N, et al. The "black evil" affecting patients with diabetes: A case of rhino orbito cerebral mucormycosis causing Garcin syndrome. *Infect Drug Resist.* 2017;10:103-8.
84. Nenoff P, Kellermann S, Horn LC, Keiner S, Bootz F, Schneider S, et al. Case report. Mycotic arteritis due to *Aspergillus fumigatus* in a diabetic with retrobulbar aspergillosis and mycotic meningitis. *Mycoses.* 2001;44(9-10):407-14.
85. Norlinah MI, Ngow HA, Hamidon BB. Angioinvasive cerebral aspergillosis presenting as acute ischaemic stroke in a patient with diabetes mellitus. *Singap Med J.* 2007;48(1):e1-4.
86. Notheis G, Tarani L, Costantino F, Jansson A, Rosenecker J, Friederici D, et al. Posaconazole for treatment of refractory invasive fungal disease. *Mycoses.* 2006;49 Suppl 1(nof, 8805008):37-41.

87. Ochi JW, Harris JP, Feldman JI, Press GA. Rhinocerebral mucormycosis: Results of aggressive surgical debridement and amphotericin B. *Laryngoscope*. 1988;98(12):1339-42.
88. Odessey E, Cohn A, Beaman K, Schechter L. Invasive mucormycosis of the maxillary sinus: extensive destruction with an indolent presentation. *Surg Infect*. 2008;9(1):91-8.
89. Oladeji S, Amusa Y, Olabanji J, Adisa A. Rhinocerebral mucormycosis in a diabetic case report. *J West Afr Coll Surg*. 2013;3(1):93-102.
90. Pandey A, Bansal V, Asthana AK, Trivedi V, Madan M, Das A. Maxillary osteomyelitis by mucormycosis: Report of four cases. *Int J Infect Dis*. 2011;15(1):e66-e9.
91. Pinto ME, Manrique HA, Guevara X, Acosta M, Villena JE, Solís J. Hyperglycemic hyperosmolar state and rhino-orbital mucormycosis. *Diabetes Res Clin Pract*. 2011;91(2):e37-9.
92. Prasad K, Lalitha RM, Reddy EK, Ranganath K, Srinivas DR, Singh J. Role of early diagnosis and multimodal treatment in rhinocerebral mucormycosis: Experience of 4 cases. *J Oral Maxillofac Surg*. 2012;70(2):354-62.
93. Rajmane VS, Rajmane ST, Patil VC, Patil AB, Mohite ST. Maxillary rhinosinusitis due to *Fusarium* species leading to cavernous sinus thrombosis. *J Mycol Med*. 2013;23(1):53-6.
94. Rao S, Kumar K, Rokade V, Khanna V, Pal C. Orbital apex syndrome due to mucormycosis caused by *Rhizopus microsporum*. *Indian J Otolaryngol*. 2006;58(1):84-7.
95. Rassi SJ, Melkane AE, Rizk HG, Dahoui HA. Sinonasal mucormycosis in immunocompromised pediatric patients. *J Pediatr Hematol Oncol*. 2009;31(12):907-10.
96. Raymundo IT, De Araújo BG, Costa CDC, Tavares JP, Lima CG, Nascimento LA, et al. Rhino-orbito-cerebral mucormycosis. *Braz J Otorhinolaryngol*. 2009;75(4):619.
97. Romano C, Miracco C, Massai L, Piane R, Alessandrini C, Petrini C, et al. Case report. Fatal rhinocerebral zygomycosis due to *Rhizopus oryzae*. *Mycoses*. 2002;45(1-2):45-9.
98. Ruoppi P, Dietz A, Nikanne E, Seppä J, Markkanen H, Nuutinen J. Paranasal sinus mucormycosis: A report of two cases. *Acta Oto-Laryngol*. 2001;121(8):948-52.
99. Sachdeva K. Rhino-oculo Cerebral Mucormycosis with Multiple Cranial Nerve Palsy in Diabetic Patient: Review of Six Cases. *Indian J Otolaryngol*. 2013;65(4):375-9.
100. Safder S, Carpenter JS, Roberts TD, Bailey N. The "black turbinate" sign: An early MR imaging finding of nasal mucormycosis. *Am J Neuroradiol*. 2010;31(4):771-4.
101. Said T, Nampoory MRN, Nair MP, Al-Saleh M, Al-Haj KH, Halim MA, et al. Safety of caspofungin for treating invasive nasal sinus aspergillosis in a kidney transplant recipient. *Transplant Proc*. 2005;37(7):3038-40.
102. Saltoğlu N, Taşova Y, Zorludemir S, Dündar IH. Rhinocerebral zygomycosis treated with liposomal amphotericin B and surgery. *Mycoses*. 1998;41(1-2):45-9.
103. Santos Gorjón P, Blanco Pérez P, Batuecas Caletro A, Muñoz Herrera AM, Sánchez González F, de la Fuente Cañibano R. Rhino-orbito-cerebral mucormycosis, a retrospective study of 7 cases. *Acta Otorrinolaringol Esp*. 2010;61(1):48-53.
104. Scheckenbach K, Cornely O, Hoffmann TK, Engers R, Bier H, Chaker A, et al. Emerging therapeutic options in fulminant invasive rhinocerebral mucormycosis. *Auris Nasus Larynx*. 2010;37(3):322-8.
105. Segal E, Menhosen MJ, Simmons S. Hyperbaric oxygen in the treatment of invasive fungal infections: A single-center experience. *Isr Med Assoc J*. 2007;9(5):355-7.
106. Shah V, Rao J, Verma V, Singh K, Agarwal B. Invasive fungal rhinosinusitis with palatal erosion in an elderly edentulous patient with uncontrolled diabetes: report of a rare case. *Gerodontology*. 2017;34(1):144-6.
107. Sharada DM, Arunkumar G, Vandana KE, Rao PS. Sino-orbital aspergillosis in a diabetic patient. *Indian J Med Microbiol*. 2006;24(2):138-40.
108. Sharma R, Bairagi S, Das S, Kumar J. Amphotericin B induced hypokalemia in a diabetic patient with rhino-orbitocerebral mucormycosis. *Anaesth Pain Intensive Care*. 2017;21(1):90-3.
109. Simmons JH, Zeitler PS, Fenton LZ, Abzug MJ, Fiallo-Scharer RV, Klingensmith GJ. Rhinocerebral mucormycosis complicated by internal carotid artery thrombosis in a pediatric patient with type 1 diabetes mellitus: A case report and review of the literature. *Pediatr Diabetes*. 2005;6(4):234-8.
110. Snaith J, Burns K, Kok J, Chen S, Cheung NW. A case of rhino-orbital mucormycosis in diabetes with haematogenous cerebral spread. *Med Mycol Case Rep*. 2016;13:22-4.
111. Sohail MA, Al Khabori M, Hyder J, Verma A. Acute fulminant fungal sinusitis: Clinical presentation, radiological findings and treatment. *Acta Trop*. 2001;80(2):177-85.
112. Strasser MD, Kennedy RJ, Adam RD. Rhinocerebral mucormycosis: Therapy with amphotericin B lipid complex. *Arch Intern Med*. 1996;156(3):337-9.
113. Swarajalakshmi M, Jyothilakshmi G. *Candida kefyr* in Invasive Paranasal Sinusitis. *Indian J Otolaryngol*. 2014;66(Suppl 1):371-4.
114. Szalai G, Fellegi V, Szabó Z, Vitéz LC. Mucormycosis mimicks sinusitis in a diabetic adult. *Ann N Y Acad Sci*. 2006;1084: 520-30.
115. Takahashi H, Hinohira Y, Hato N, Wakisaka H, Hyodo J, Ugumori T, et al. Clinical features and outcomes of four patients with invasive fungal sinusitis. *Auris Nasus Larynx*. 2011;38(2):289-94.
116. Talmi YP, Goldschmied-Reouven A, Bakon M, Barshack I, Wolf M, Horowitz Z, et al. Rhino-orbital and rhino-orbito-cerebral mucormycosis. *Otolaryng Head Neck*. 2002;127(1):22-31.
117. Talwalkar PG. Rhino-oculo-cerebral mucormycosis in patients with type 2 diabetes mellitus. *J Assoc Physicians India*. 2009;57:407-9.
118. Tan KT, Ong PL, Poh WT, Cheah JS. Aspergillosis of sphenoid sinus presenting as a pituitary tumour. *Singapore Med J*. 1988;29(4):410-2.
119. Tarani L, Costantino F, Notheis G, Wintergerst U, Venditti M, Di Biasi C, et al. Long-term posaconazole treatment and follow-up of rhino-orbital-cerebral mucormycosis in a diabetic girl. *Pediatr Diabetes*. 2009;10(4):289-93.
120. Thajeb P, Thajeb T, Dai D. Fatal strokes in patients with rhino-orbito-cerebral mucormycosis and associated vasculopathy. *Scand J Infect Dis*. 2004;36(9):643-8.
121. Timóteo CA, Corrêa APS, Coleté JZ, Aranega AM, Júnior IRG. Survival without neurological impairment of a patient with rhino-orbito-cerebral zygomycosis. *J Craniofac Surg*. 2016;27(4):e376-e8.
122. Tugsel Z, Sezer B, Akalin T. Facial swelling and palatal ulceration in a diabetic patient. *Oral Surg Oral Med Oral Pathol Oral Radiol Endod*. 2004;98(6):630-6.
123. Uğurlu ŞK, Selim S, Kopar A, Songu M. Rhino-orbital mucormycosis: Clinical findings and treatment outcomes of four cases. *Turk Oftalmol Derg*. 2015;45(4):169-74.
124. Vaidyanathan V, Shetty K. Rhinocerebral mucormycosis: A series of 3 cases. *Ann Trop Med*. 2012;56(6):591-3.
125. Valera FCP, Lago TD, Tamashiro E, Yassuda CC, Silveira F, Anselmo-Lima WT. Prognosis of acute invasive fungal rhinosinusitis related to underlying disease. *Int J Infect Dis*. 2011;15(12):e841-e4.
126. Vos FI, Reitsma S, Adriaansen GFJPM, Fokkens WJ. Eye for an eye: Near-fatal outcome of fungal infection in a young, diabetic girl. *BMJ Case Rep*. 2018;2018.bcr2017223059.
127. Wipfler P, Pilz G, Golaszewski S, Luthringhausen G, Berr F, Kemmerling R, et al. Invasive aspergillosis presenting with a painless complete ophthalmoplegia. *Clin Neurol Neurosurg*. 2010;112(1):85-7.
128. Wüppenhorst N, Lee MK, Rappold E, Kayser G, Beckervordersandforth J, De With K, et al. Rhino-orbitocerebral zygomycosis caused by *Conidiobolus incongruus* in an immunocompromised patient in Germany. *J Clin Microbiol*. 2010;48(11):4322-5.
129. Yohai RA, Bullock JD, Aziz AA, Markert RJ. Survival factors in rhino-orbital-cerebral mucormycosis. *Surv Ophthalmol*. 1994;39(1):3-22.
130. Yoon JS, Park HK, Cho NH, Lee SY. Outcomes of three patients with intracranially invasive sino-orbital aspergillosis. *Ophthalm Plast Reconstr*. 2007;23(5):400-6.
131. Yoon YK, Kim MJ, Chung YG, Shin IY. Successful treatment of a case with rhino-orbital-cerebral mucormycosis by the combination of neurosurgical intervention and the sequential use of amphotericin B and posaconazole. *J Korean Neurosurg Soc*. 2010;47(1):74-7.
132. Cho HJ, Jang MS, Hong SD, Chung SK, Kim HY, Dhong HJ. Prognostic factors for survival in patients with acute invasive fungal rhinosinusitis. *Am J Rhinol Allergy*. 2015;29(1):48-53.
133. Turner JH, Soudry E, Nayak JV, Hwang PH. Survival outcomes in acute invasive fungal sinusitis: a systematic review and quantitative synthesis of published evidence. *Laryngoscope*. 2013;123(5):1112-8.
134. Fokkens WJ, Lund VJ, Hopkins C, Hellings PW, Kern R, Reitsma S, et al. European Position Paper on Rhinosinusitis and Nasal Polyps 2020. *Rhinology*. 2020; 58(Suppl S29): 1-464.

135. Frater JL, Hall GS, Procop GW. Histologic features of zygomycosis: emphasis on perineural invasion and fungal morphology. Arch Pathol Lab Med. 2001;125(3):375-8.
136. King GL. The role of inflammatory cytokines in diabetes and its complications. J Periodontol. 2008;79(8 Suppl):1527-34.
137. Liu M, Spellberg B, Phan QT, Fu Y, Fu Y, Lee AS, et al. The endothelial cell receptor GRP78 is required for mucormycosis pathogenesis in diabetic mice. J Clin Invest. 2010;120(6):1914-24.
138. Schell WA. Unusual fungal pathogens in fungal rhinosinusitis. Otolaryngol Clin North Am. 2000;33(2):367-73.
139. Frater JL, Hall GS, Procop GW. Histologic features of zygomycosis: emphasis on perineural invasion and fungal morphology. Arch Pathol Lab Med. 2001;125(3):375-8.