



Basement Membrane Antibodies in Alport's Syndrome

Somnate Boonpucknavig¹, Vijitr Boonpucknavig² and Wiwat Tapaneeyaolarn³

The advent of new biochemical and molecular biological techniques as well as the availability of new experimental models have for the past few years led to great progress in the elucidation of the composition of normally and pathologically altered collagenous and non-collagenous connective tissue components, including those of basement membranes (BM).¹⁻³ In addition, specific polyclonal and monoclonal antibodies have been of increasing importance as an analytical tool in this field.^{4,5} Of special interest is, of course, the utilization of this knowledge for studies of hereditary and acquired diseases affecting BM.⁶⁻⁸ The interest is focussed on autoimmune diseases involving BM, such as bullous pemphigoid (autoantibodies against BM of squamous epithelia) and Goodpasture syndrome (GPS-autoantibodies against glomerular and alveolar BM). For the latter, i.e. a primary autoimmune glomerular disease, one relevant antigen has been identified as the non-collagenous domain (NC-1) of collagen type IV.⁹⁻¹² However, in autoimmune diseases involving BM in a secondary fashion, i.e. via the deposition of immune complexes not involving BM-antigens, such as

SUMMARY By the indirect immunofluorescent technique, sera from patients with Alport's syndrome showed a reaction with the basement membrane of the capillary wall of glomeruli and peritubular vessels and nearby interstitial tissue of normal monkey and mouse kidney as a substrate. It also revealed bright staining to the matrix surrounding the clusters of EHS tumor cells and stromal tissues. These reactions were caused by autoantibodies present in these sera. These findings were supported by the detection of antilaminin, nidogen and anti collagen type VI in the sera by ELISA method. These evidences suggest that the Alport's patients developed stage of autoimmunity. The exact causes were not so clear, but seemed to be due to multiple factors.

systemic lupus erythematosus (SLE), the GBM is not the direct target for the autoimmune reaction, but rather damaged as an "innocent bystander". The composition of the BM and the exposure of appropriate target structures interacting with certain parts of immune complexes are of great importance in both categories of BM pathology.

The different specificity of autoantibodies in sera from patients with bullous pemphigoid as apposed to GPS already pointed to the fact, that the BM in different organs may show a different qualitative or/and quantitative composition. It has thus been hypothesized that GMB and alveolar basement membranes (ABM) possess NC-1 components that carry slightly different epitopes as compared to

those found in other, i.e. epithelial basement membranes (EBM). In addition, there may be age related differences in the composition of BM.³ Wick *et al.* have suggested that the characteristic binding pattern of BM autoantibodies in GPS patients may be due to the fact that GBM and ABM are exposed to the highest

From the ¹Department of Pathobiology, Faculty of Science, Mahidol University, Rama 6 Road, Bangkok 10400, Thailand, ²Department of Pathology, and ³Department of Pediatrics, Faculty of Medicine, Ramathibodi Hospital, Mahidol University, Bangkok 10400, Thailand.

Correspondence: Dr. Somnate Boonpucknavig

concentrations of internal (blood filtration) and external (inhalation) potentially toxic agents that may alter the antigenic structure and/or exposure of certain epitopes in these two organs.¹³

An especially striking example for the variation in BM composition and the use of these differences for biochemical and immunopathological studies of BM constituents are tumors that produce large amounts of BM material. Such tumors have one advantage, that is one can extract BM constituents in high yield without harsh proteolytic treatment. The two best known tumors of this kind are the Englebreth-Holm Swarm (EHS) transplantable murine tumor and the human cylindroma (= turban tumor). The matrix of the former contains the "Goodpasture antigen(s)" which GPS sera strongly react with the EHS matrix, but sera from bullous pemphigoid patients do not.¹⁴ In contrast, the sera from the latter patients give a clear cut reaction with BM produced by the human cylindroma while GPS sera are negative on this substrate.

The present report deals with indirect immunofluorescence (IF) studies of sera from patients with proven Alport's syndrome on various normal and murine tissues, including the EHS tumor. Alport's syndrome (Alport-type familial nephritis, AS) is a hereditary disease mainly affecting males, characterized by progressive renal insufficiency, hearing loss and occasionally-ocular lesions, e.g. anterior lenticonus.^{6,15,16} Electron microscopical findings include changes of GBM and often also the tubular BM (TBM) and Bowman's capsule. Biochemical and/or antigenic alterations of the GBM in AS were first suggested by other investigators that (a) AS patients received a renal transplant readily developed antibodies against the GBM of the normal kidney grafts,¹⁷ and (b) sera from GPS patients did not bind to the GBM of AS kidney sections in

IF.¹⁸ It thus seems, that AS GBM either lacks certain antigenic components or possesses them in a masked form not accessible to e.g. GPS antibodies.

Using GPS sera and sera from AS post renal transplant patients, respectively, Kashtan *et al.*¹⁹ analyzed normal EBM proteins using GPS sera and a serum from an AS patient with anti-GBM antibody induced allograft nephritis as probes in Western-blotting. As expected, GPS antibodies reacted with a 28 KD monomer and also the 24 and 26 KD monomers of NC-I, but the AS serum only recognized the 26 KD moiety. Interestingly, the AS serum reacted with all EBM's of healthy controls and all unaffected male kindred members, but not with EBM of affected AS patients. In the present context it is important to note that GPS sera in this study did not react with a GBM of male AS patients. Again this supports the concept that the antigen(s) involving in AS and GPS are different.

In a previous study Timpl and his colleagues reported on the development of a murine model for GPS where mice were immunized with NC-I obtained from the EHS mouse tumor and complete Freund's adjuvant.²⁰ The present experiments are designed to further analyze the reaction pattern of AS sera on various normal human and murine tissues, including the EHS tumor.

MATERIALS AND METHODS

Patients and Control

Sera from 3 patients having clinical family history and renal pathological characteristics of Alport's Syndrome were included in this study. They all had proteinuria, hematuria and hearing loss. Sera from 5 normal individuals were also tested as normal control.

Antibodies

The following polyclonal anti-

bodies were prepared in rabbits or goats and purified by affinity chromatography as described in detail elsewhere.²¹

- anti-bovine collagen type I (a-I)
- anti-bovine collagen type III (a-III)
- anti-bovine procollagen type III (a-p III)
- anti-murine (EHS-tumor derived collagen type IV (a-IV)
- anti-murine (EHS-tumor derived) laminin (a-lam)
- anti-murine (EHS-tumor derived) non-collagenous globular domain (NC-I) of collagen type IV
- anti-human collagen type V (a-V)
- anti-human collagen type VI (a-VI)
- anti-human fibronectin

All antibodies except anti-laminin (goat) were derived from rabbits. The antibodies prepared against non-human antigenic material showed a high degree of cross-reactivity with the respective human material as described previously.^{3-5,20-23} Optimal dilutions of the antibodies as described in previous experiments were used.²¹

Immunofluorescence

Indirect immunofluorescent staining of unfixed frozen mouse Englebreth-Holm sarcoma (EHS) tissue section was performed following the standard procedure.²² Primary antiserum used in double staining and blocking test was as mentioned above. Secondary antibodies used were FITC-labelled rabbit antihuman Igs, swine antigoat (antilaminin), swine antirabbit IgG, TRITC labelled chicken antihuman IgG. Negative control was obtained from normal human and rabbit sera.

Direct immunofluorescent staining of unfixed frozen patients's kidney obtained from biopsy was performed using antihuman IgG, IgM, IgA, complement and fibrinogen conjugate with FITC.

Enzyme linked immunosorbent assays (ELISA)

ELISA was performed as described in detail by Von der Mark *et al.*²⁴ Briefly, flat bottom microtiter plates (Greiner, Kremsmunster, Austria) were coated with appropriate antigens at the concentration of 25-50 $\mu\text{g}/\text{ml}$, left overnight, washed and stored at 4°C until use. Serial dilutions of the patients' sera, positive and negative controls were added to the wells and the reaction visualized with a peroxidase labelled conjugate. Antibody activity was expressed as OD at 492 nm read in a spectrophotometer (Dynatech, Santa Monica, Ca, USA).

Histology and Electron Microscopy

Kidney tissues from biopsy were fixed in formalin and embedded in paraffin for light microscope.²⁵ Each portion of the kidney biopsy from patients was immediately put in fresh, cold 4% glutaraldehyde solution and left for 1 hour. The tissue was post fixed with cold 1% osmium tetroxide in 0.1 M phosphate buffer solution for 1 hour. After dehydration in a graded series of ethanol solution, the blocks of tissue were embedded in Epon 812. The sections were cut at approximately 1 μ and were stained with 1% toluidine blue 0 in 1% borax. These thick Epon sections were used to identify the glomeruli by light microscopy. Thin sections were cut with an ultramicrotome, using glass knives, and were mounted on grids. After doubling staining with uranyl acetate and lead acetate the sections were examined and photographed using a Hitachi HS-8 electron microscope.²⁵

RESULTS

Light microscopy

Glomerular capillary wall were irregularly thickened. Focal and segmental mesangial cell hyperplasia with increasing matrix were noted. Thickening of Bowman's capsule associated with hyperplasia of the

parietal epithelial lining cells and periglomerular fibrosis was commonly found (Fig. 1). Clusters of interstitial foam cells were seen (Fig. 2).

Electron microscopy

Ultrastructural lesions consisted of marked thickening of the glomerular basement membrane. The lamina densa, in the thickening areas was split to form multiple, thin electron-dense laminated trabeculated

appearance (Fig. 3). Similar alterations were present in the Bowman's capsule and tubular basement membrane. There was a mild to moderate increase in mesangial cells and matrix. (Fig. 4). Fusion of foot processes and villous transformation of the podocytes were present.

Immunofluorescence

Indirect Staining

In all patients, the sera gave similar positive staining reaction to

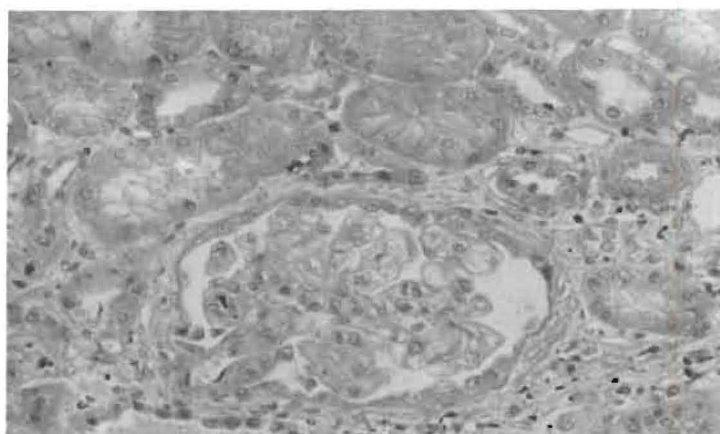


Fig. 1 A glomerular with periglomerular fibrosis. The glomerular basement membrane of certain capillary loops shows double contour appearance. (H & E x 100).

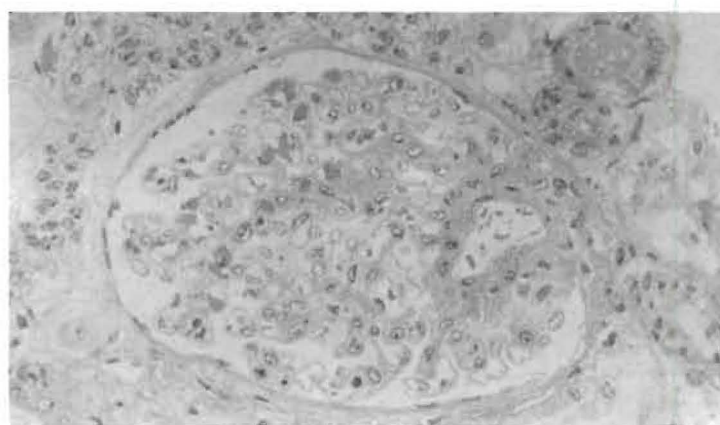


Fig. 2 Showing mild, segmental, increasing mesangial matrix, Note clusters of foam cells in the periglomerular interstitial tissue. (Electron microscopy thick section, toluidin blue x 200).

some tissue components of normal mouse and monkey kidneys. These included some portions of glomerular capillary walls particularly in paramesangial areas, mesangial matrix (Fig. 4) and some part of Bowman's capsules. The most prominent staining activity was seen at the wall of peritubular capillaries and nearby interstitial tissue (Fig. 5).

Immunofluorescence techniques on mouse EHS using Alport's sera, strongly stained the stromal tissue and matrix surrounding the clusters of tumor cells (Fig. 6). Double staining experiments using AS sera and antibodies to various connective tissue components were done. The results revealed that AS sera showed co-distribution reaction on the basement membrane of capillary walls of the glomeruli, basement membrane of tubules and also the matrix around the tumor cells of the EHS sarcoma with antilaminin, anticollagen type

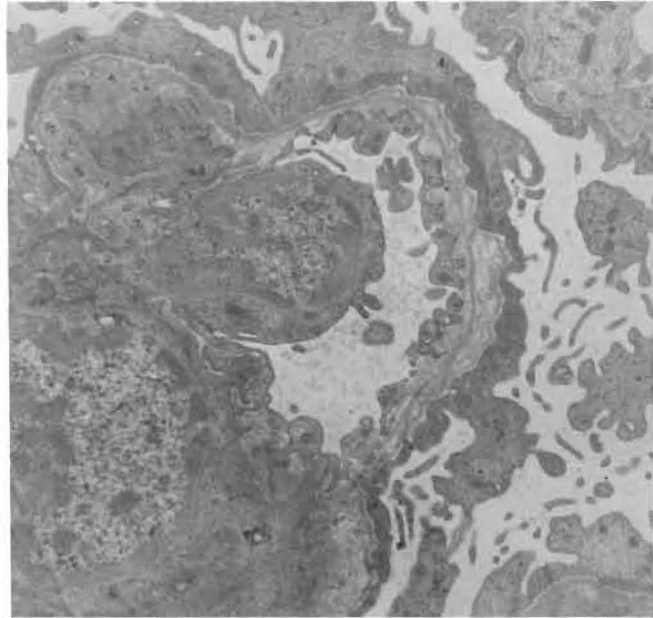


Fig. 3 Showing splitting and lamination of lamina densa of a glomerular capillary wall. (Electron microscopy x 25,000).

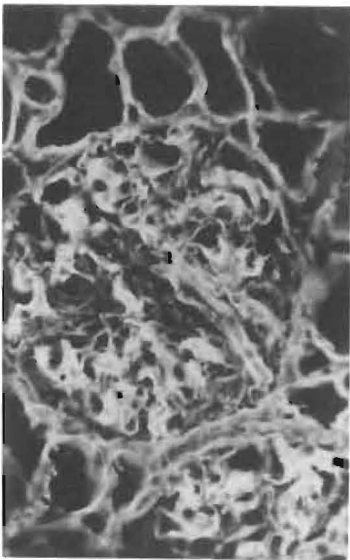


Fig. 4 A glomerulus of monkey kidney showing positive staining with patient's serum in mesangial areas and extending along certain capillary wall, (Indirect immunofluorescence x 400).

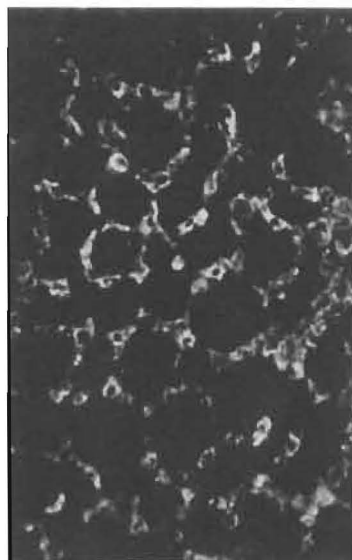


Fig. 5 Tubulo-interstitial tissue of monkey kidney showing positive staining with patient's serum in the wall of peritubular capillaries and interstitial tissue. (Indirect immunofluorescence x 400).

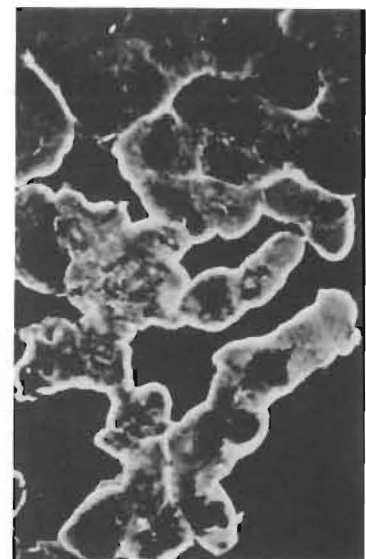
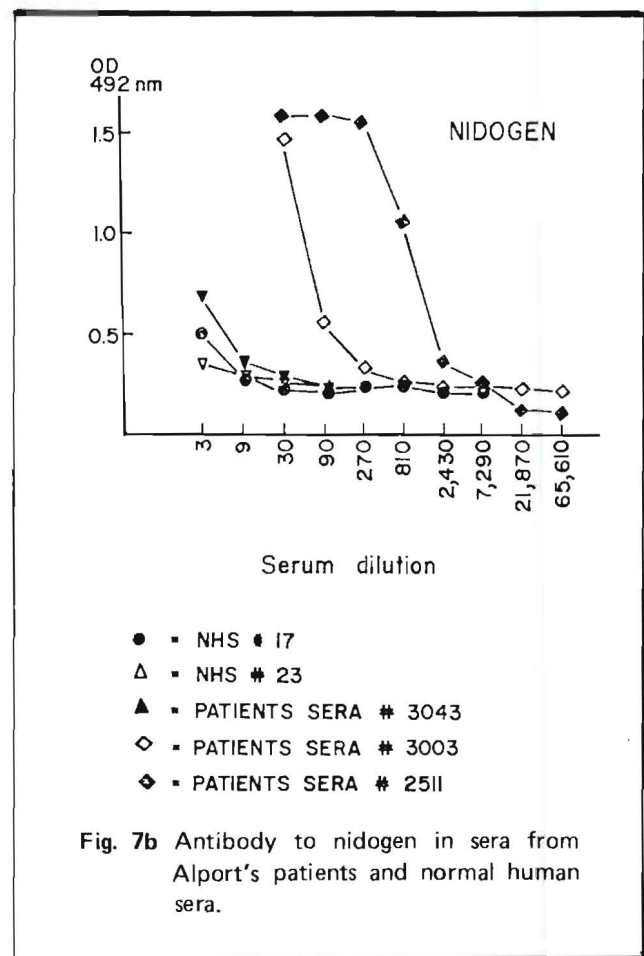
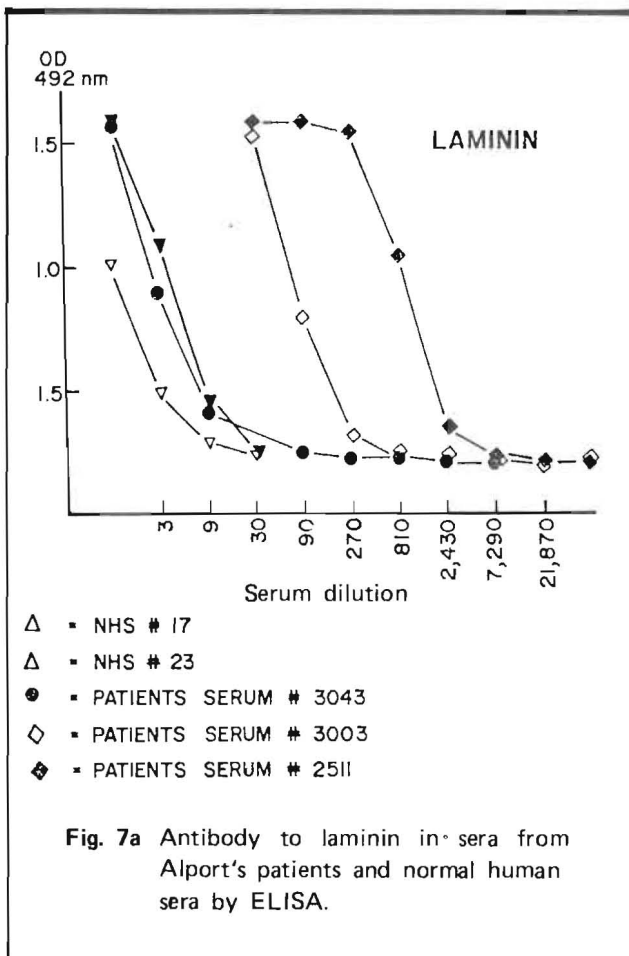


Fig. 6 EHS tumor showing positive staining with patients sera in the matrix around the tumor cells (Indirect immunofluorescence x 400).



IV, anticollagen type V, antifibronectin, antiglobular domain (NC-1) of collagen type IV. Moreover, the reaction with co-distribution was also noted in the interstitial stroma of a mouse tumor (EHS) and interstitial tissues nearby the tubules with anticollagen type VI. In addition, Alport's sera showed no codistribution reaction with the interstitial tissues around the tubules with anti-procollagen type III, anticollagen type I, and anticollagen type III.

Alport's sera could block the reaction of the basement membrane of the glomeruli, tubules of the kidney and the matrix surrounding EHS sarcoma cells with the pool antisera of antilaminin, anticollagen type IV, anticollagen type V, anti fibronectin, and anti NC-1. These antibodies could block the reaction of the Alport's sera by showing reduction of staining

after blocking reaction. Subsequently anticollagen type VI could block reaction to the interstitial tissue nearby the tubules of the kidney and the interstitial stroma of EHS by the Alport's sera in mimic degree.

Direct staining

There were no deposits of anti-human IgG, IgM, IgA, complement and fibrinogen on these kidneys from AS patients.

Reactivity in ELISA

Since the pattern of fluorescence of the three sera on frozen sections of various tissues, especially the kidney, and the EHS tumor, showed a clear cut reactivity with BM and interstitial components. The ELISA was performed for further characterization. All sera were negative for antibodies to collagens IV and V, and to NC-1

the globular domain of IV = the goodpastures' Ag (not shown in the data). However, two sera (#2511 and 3003) gave positive results with laminin (Fig. 7a) and nidogen (Fig. 7b). One of them (#3003) also reacted weakly with type VI collagen (Fig. 7c).

DISCUSSION

Light microscopic and electron microscopic examinations of kidney biopsy obtained from patients with Alport's Syndrome revealed similar alterations as previously described.^{25,26} Direct immunofluorescence study showed the same findings as reported by McCoy.¹⁶ No deposits of anti IgG, IgM, IgA, C₃, C_{1q}, fibrinogen in glomeruli were noted in these patients, only B_{1c} and fibrin deposits appeared in sclerotic glomeruli. Indirect immunofluorescent staining of the sera from the patients with

Alport's Syndrome with normal human kidney showed the same results as obtained by Habib and her colleagues that it was indistinguishable from the antisera against type IV, V, and laminin.¹⁵ However, even the monkey and mouse kidneys were used as a substrate, the staining pattern along the basement membrane of glomerular and tubular capillary walls yielded the same results. In addition, when mouse EHS was used as a substrate, the Alport's serum stained very strongly to the matrix surrounding the clusters of tumor cells which contained basement membrane components. This supports the fact that Alport's sera contains autoantibodies to laminin and nidogen components of glomerular and tubular basement membranes (Fig. 7a, b). Moreover, there are evidences that Alport's sera also contained anti-collagen type VI antibody because the sera gave a positive staining to mesangial matrix and interstitial tissue of the monkey and mouse kidneys and interstitial stromal tissue of EHS. In addition, ELISA study of serum of a patients revealed anti collagen type VI antibody (Fig. 7c).

The rest of them perhaps had antibodies against other collagen which were not tested in the present study. In the blocking reaction when the Alport's sera were utilized as primary sera and the pool of anti-laminin, anticollagen type IV and anti NC₁ and antifibronectin as secondary sera, it yielded less reduction of staining. This could be explained that the Alport's sera contained autoantibody not only the above mentioned ones but also antinidogen which was not present in the pool antisera. Therefore, antinidogen in the Alport's sera was not blocked and could still offer staining. Even though when a single serum was used as secondary serum, such as anti-laminin, or anticollagen type IV, the blocking reaction was not complete as the antinidogen was still in the Alport's sera, resulting in only re-

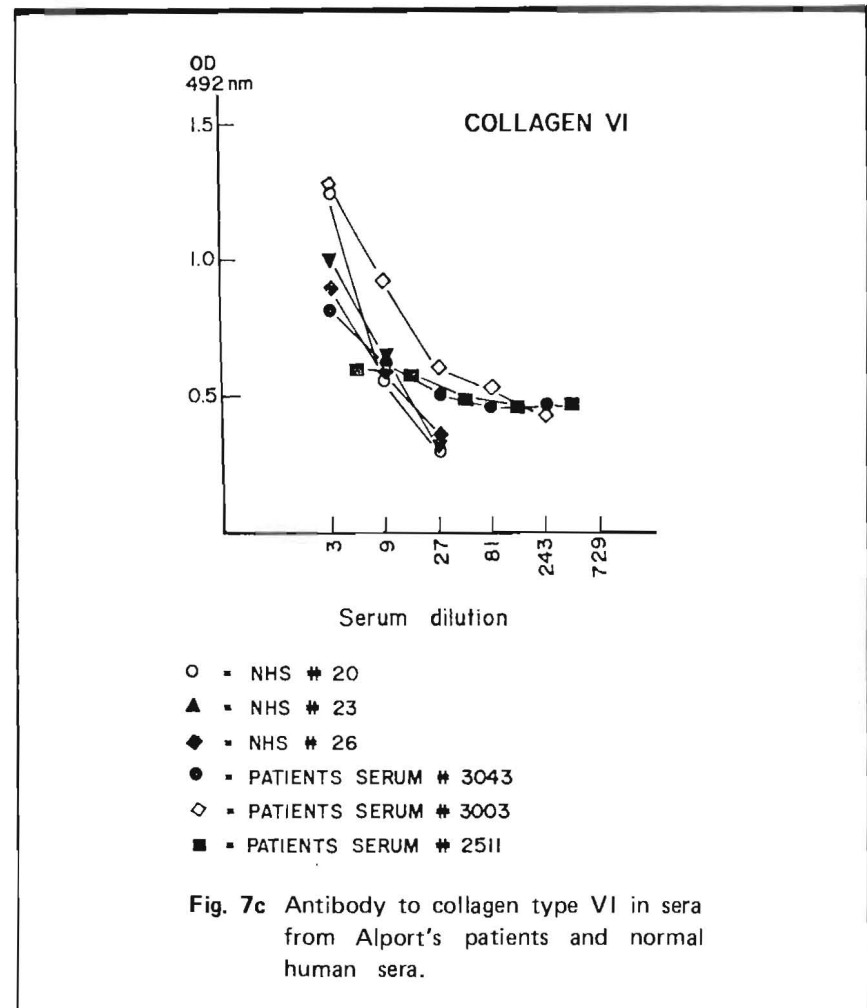


Fig. 7c Antibody to collagen type VI in sera from Alport's patients and normal human sera.

duction of staining. The reasons why the Alport's patients had autoantibodies to laminin and nidogen even though these patients were not transplanted could be that autoantibodies might have crossed reactivity with some microbial or parasitic antigen that had infected these patients²⁷ or that the alteration of autologous BM by the process of the disease of by participation of environmental elements such as the drug used.²⁷ It is clear that autoimmunity is a result of multiple factors. In general, it has been considered that the AS type of hereditary nephritis is an autosomal dominant trait.^{6,28} There have been no reports concerning HLA relationship.²⁸ However, in our patients there were no definite family histories. Our finding is supported by McCoy's report that

the confusing nature of the clinical presentation was compounded by the difficulty in obtaining accurate family histories because the disease may skip generation within affected pedigree.¹⁶

ACKNOWLEDGEMENTS

We would like to thank Dr. Timpl for providing antibodies to connective tissue components and Dr. Helga von der Mark for the performance of ELISA and Prof. G. Wick for giving a EHS tumor.

REFERENCES

1. Fleischmajer R, Olsen BR, Kuhn K (eds). Biology, chemistry, and pathology of collagen. Ann NY Acad Sci 1985; 460.
2. Mayne R, Burgeson RE (eds). Biology of the extracellular matrix. Structure

- and function of collagen types. New York : Academic Press, 1987.
3. Timpl R, Dziadek M. Structure, development and molecular pathology of basement membranes. *Int Rev Exp Pathol* 1986; 29 : 1-112.
 4. Furthmayr H (ed). *Immunochemistry of the extracellular matrix*. Vol. 1/11. Boca Raton, Fla : CRC Press Inc., 1982.
 5. Kefalides NA (ed). *Biology and chemistry of basement membranes*. New York-London : Academic press, 1978.
 6. Spear GS. Hereditary nephritis (Alport's syndrome) 1983. *Clin Nephrol* 1984; 21 : 3-6.
 7. Krischbaum BB. Glomerular basement membrane and anti-GBM antibody disease. *Nephron* 1981; 29 : 205-8.
 8. Beutner EH, Chorzelski TP, Bean SF. *Immunopathology of the skin*. 2nd (ed). New York : Jphn Wiley & sons, 1979.
 9. Wieslander J, Bygren P, Heingegard D. Isolation of the specific glomerular basement membrane antigen involved in Goodpasture syndrome. *Proc Natl Acad Sci USA* 1984; 81 : 1544-8.
 10. Butkowski RJ, Wieslander J, Wisdom BJ, Barr JF, Noelken ME, Hudson BG. Properties of the globular domain of type IV collagen and its relationship to the Goodpasture antigen. *J Biol Chem* 1985; 260 : 3739-47.
 11. Sans J, Wieslander J, Langeveld JPM, Quinones, Hudson B. Identification of the Goodpasture antigen as the 3(IV) chain of collagen IV. *J Biol Chem* 1988; 263 : 13374-80.
 12. Timpl R, Oberbaumer I, Von der Mark H, Bode W, Wick G, Weber S, Engel J. Structure and Biology of the globular domain of basement membrane type IV collagen. In : *Biology, chemistry and pathology of collagen* Fleischmajer R, Olsen BR, Kulm (eds). *Ann NY Acad Sci* 1985; 460 : 58-72.
 13. Wick G, Von der Mark H, Dietrich H, Timpl R. Globular domain of basement membrane collagen induced autoimmune pulmonary lesions in mice resembling human Goodpasture disease. *Lab Invest* 1986; 55 : 308-17.
 14. Wick G, Munro V, Gebhart W, Timpl R. Basement membrane producing tumors as antigenic substrate for the demonstration of antibasement membrane antibodies. In : *Defined immunofluorescence and related cytochemical methods*. Neutner EH, Nisengard RJ, Albini B (ed). *Ann NY Acad Sci* 1983; 420 : 267-74.
 15. Habib R, Gubler MC, Hinglais N, Noel LH, Droz D, Levy M, Mahieu P, Foidart JM, Perrin D, Bois E, Grunfeld JP. *Kidney Int* 1982; 21/suppl 11 : S20-S28.
 16. McCoy R, Johnson HK, Stone WJ, Wilson CB. Absence of nephritogenic GBM antigen(s) in some patients with hereditary nephritis. *Kidney Int* 1982; 21 : 642-52.
 17. Wilson CB. Individual and strain differences in renal basement membrane antigens. *Transplant Proc* 1980; 12/suppl : 69-73.
 18. Kleppel M, Kashtan CE, Butkowaski RJ, Fish AJ, Michael AF. Alport familial nephritis. Absence of 28 kilodalton non-collagenous monomers of type IV collagen in glomerular basement membrane. *J Clin Invest* 1987; 80 : 263-6.
 19. Kashtan C, Fish CJ, Kleppel MM, Yoshioka K, Michael AF. Nephritogenic antigen determinants in epidermal and renal basement membranes in kindred with Alport-type familial nephritis. *J Clin Invest* 1986; 78 : 1035-44.
 20. Timpl R, Wick G, Furthmayr H, Lapiere CM, Kuhn K. Immunological properties of procollagen from dermatosparactic calves. *Curr J Biochem* 1973; 32 : 584-91.
 21. Wick G, Furthmayr H, Timpl R. Purified antibodies to collagen : an immunofluorescence study of their reaction with tissue collagen. *Int Arch Allergy Appl Immunol* 1974; 48 : 664-79.
 22. Wick G, Nowack H, Halm E, Timpl R, Miller EJ. Visualization of type I and II collagens in tissue section by immunohistologic techniques. *J Immunol* 1974; 117 : 298-303.
 23. Timpl R, Wick G, Gay St. Antibodies to distinct types of collagens and procollagens and their application in immunohistology. *J Immunol Methods* 1977; 18 : 165-82.
 24. Von der Mark H, Oberbaumer I, Timpl R, Kemler R, WG. Immunochemical and autoantigenic properties of the globular domain of basement membrane collagen (type IV). *Eur J Biochem* 1985; 146 : 555-62.
 25. Boonpucknavig V, Boonpucknavig S, Bhamarapavati N. Plasmodium berghei infection in mice, *Am J Path* 1973; 70 : 89-99.
 26. Spear GS, Withworth JM, Konigsmark BM. Hereditary nephritis with Nerve deafness. *Am J Med* 1970; 49 : 52-63.
 27. Shoenfeld Y, Isenberg DA. Mycobacteria and autoimmunity. *Immunol Today* 1988; 9 : 178-82.
 28. Rogers MC, Kurtzman NA, Simon JR MB, White MG. Familial benign essential hematuria. *Arch Intern Med* 1978; 181 : 257-62.