

Expression of cysteinyl leukotriene receptor GPR17 in eosinophilic and non-eosinophilic chronic rhinosinusitis with nasal polyps

Kun Chen,^a Zhijian Yu,^b Jun Yang,^{a,*} Huabin Li^{a,*}

Abstract

Background: The cysteinyl leukotrienes (cysLTs) are proinflammatory lipid mediators that act on the type 1 cysLT receptor (CysLT1R) in the pathogenesis of chronic rhinosinusitis with nasal polyps (CRSwNP). GPR17, a G protein-coupled orphan receptor with homology to the cysLT receptors, has been proposed as a damage sensor during inflammation. However, the expression and correlation of GPR17 and CysLT1R in eosinophilic CRSwNP (E CRS) and non-eosinophilic CRSwNP (non-E CRS) have not been well investigated.

Objective: To evaluate the expression of GPR17 and its correlation with CysLT1R in the 2 CRSwNP subsets.

Methods: Polyp tissues were collected from CRSwNP subjects (15 E CRS and 14 non-E CRS), and uncinate processes were collected from 12 CRSsNP subjects and 13 control subjects. The mRNA and protein levels of GPR17 and CysLT1R were examined using qRT-PCR, immunohistochemistry, and western blotting. Additionally, the correlation between GPR17 and CysLT1R at the mRNA and protein levels was evaluated. All assays were performed in a blinded manner.

Results: Polyp tissues exhibited significantly increased GPR17 expression relative to uncinate process tissues from CRSsNP patients, or healthy controls ($P=0.0012$ and $P<0.0001$, respectively). Compared with the non-E CRS subset, the E CRS subset showed significantly increased GPR17 expression. Moreover, the GPR17 expression was positively correlated with CysLT1R in nasal polyps.

Conclusions: The increased expression of GPR17 in nasal polyps and the differential expression between eosinophilic and non-eosinophilic CRSwNP subsets suggest that these subsets may have distinct pathogenic mechanisms. The positive correlation between GPR17 and CysLT1R in polyp tissues might imply substantial regulatory mechanisms that must be elucidated.

Keywords: cysteinyl leukotriene; GPR17; CysLT1R; chronic rhinosinusitis; nasal polyps

From:

^a Department of Otolaryngology-Head and Neck Surgery, Xinhua Hospital, Shanghai Jiaotong University School of Medicine, Shanghai, China.

^b Department of Otolaryngology, Zhuhai People's Hospital, Zhuhai Hospital Affiliated with Jinan University, Zhuhai, China.

Corresponding author:

1. Huabin Li

Department of Otolaryngology-Head and Neck Surgery, Xinhua Hospital, Shanghai Jiaotong University School of Medicine, No. 1665, Kongjiang Road, Shanghai, 200092.China.
E-mail: allergyli@163.com

2. Jun Yang

Department of Otolaryngology-Head and Neck Surgery, Xinhua Hospital, Shanghai Jiaotong University School of Medicine, No. 1665, Kongjiang Road, Shanghai, 200092.China.
E-mail: yangjun@xinhumed.com.cn

Introduction

Chronic rhinosinusitis (CRS) is a common disease that affects 4-10% of the global population, which is characterized by chronic inflammation of the mucosa of the nose and paranasal sinuses that persists for a minimum of 12 weeks. CRS can generally be classified into 2 subtypes: CRS with nasal polyps (CRSwNP) and CRS without nasal polyps (CRSsNP).^{1,2} Recently, CRSwNP was proposed to be a heterogeneous disorder with variable clinical manifestations in different regions, and CRSsNP is considered an inflammatory condition that is associated with a Th1-immune response.² Based on the extent of tissue eosinophilia, it has been proposed that CRSwNP be subclassified into eosinophilic and non-eosinophilic subtypes, each of which is characterized

by distinct degrees, therapeutic strategies, and prognoses.^{3,4} Despite numerous studies designed to clarify the cellular and molecular features of differential chronic inflammation between patients with eosinophilic CRSwNP (E CRS) and patients with non-eosinophilic CRSsNP (non-E CRS), the molecular mechanisms underlying the discrepancy remain largely unknown.⁵

The P2Y-like, G protein-coupled receptor GPR17 is phylogenetically located at an intermediate position between P2Y and cysteinyl leukotriene (cysLT) receptors; it is a dual receptor for uracil nucleotides and cysLTs (LTC₄, LTD₄, and LTE₄) and is highly expressed in organs undergoing ischemic damage.^{6,7} Additionally, the *in vivo* inhibition of GPR17 by cysLT receptor antagonists dramatically reduces ischemic damage in a rat focal ischemia model, suggesting that GPR17 is the common molecular target mediating brain damage by cysLTs.⁷ These proinflammatory lipid mediators (LTC₄, LTD₄, and LTE₄) have been specifically implicated in human bronchial asthma via the type 1 cysLT receptor (CysLT1R), and antagonism of CysLT1R and GPR17 with the specific inhibitor montelukast reduces the levels of inflammatory cytokine expression.^{8,9} However, a recent study showed that GPR17 negatively regulates CysLT1R functions in allergic pulmonary inflammation.¹⁰ We thus propose a possible pathological role of GPR17 in nasal polyps; this is the first study to examine the expression of GPR17 in sinus tissues.

Significant pathologic findings in nasal polyp tissues include intense eosinophilic inflammation, leading to a need for more aggressive courses of medical treatments and surgical therapies.¹¹ In recent years, there has been increasing interest in the potential role of cysLTs in the pathogenesis of CRSwNP. For instance, Steinke et al.¹¹ showed that cysLTs levels are significantly increased in E CRS patients but not in non-E CRS patients and healthy controls. Our previous study also revealed the differential expression of cysLTs and its receptors (CysLT1R and CysLT2R) between the two CRSwNP subsets.¹³ It is thus necessary to address whether GPR17, as one of the cysLT receptors, is associated with the phenotype of CRSwNP.

Materials and methods

Patients

Adult patients with CRSwNP (15 E CRS and 14 non-E CRS patients), or CRSsNP (12 patients) were enrolled from the Department of Otolaryngology, Head and Neck Surgery of Xinhua Hospital, Shanghai Jiaotong University School of Medicine. The diagnoses of CRSwNP and CRSsNP were made based on medical history, nasal endoscopy, and computed tomography (CT) scans of the paranasal cavities, in accordance with the current European guidelines on rhinosinusitis and nasal polyps.¹ Skin-prick tests with a panel of aeroallergens (pollens, dust mites, pets, molds, etc.) were performed to evaluate the atopic status of the patients. Asthma was diagnosed by a pneumologist based on the disease history and an evaluation of airway responsiveness. None of the subjects used oral or nasal steroids or other immune-modulating drugs for 4 weeks prior to surgery. Patients who had a previous history of acute infection, fungal sinusitis, cystic fibrosis, antrochoanal

polyps, or gastroesophageal reflux disease were excluded from the study. During endoscopic surgery, polyp tissues were sampled from patients with CRSwNP, whereas uncinata process tissues were sampled from patients with CRSsNP. As healthy controls, 13 patients undergoing septoplasty because of anatomic variations were enrolled, and the uncinata process was sampled during surgery. The demographic data of all subjects enrolled in this study are listed in **Table 1**. This study was approved by the ethics committee boards at the Xinhua Hospital Affiliated Shanghai Jiaotong University School of Medicine, and written informed consent was obtained from each subject. According to eosinophil levels, the CRSwNP patient population was divided into E CRS and non-E CRS.¹⁴ In summary, the cutoff value separating E CRS from non-E CRS was set at 8 eosinophils/high-power field (HPF); a polyp with ≥8 eosinophils/HPF was defined as E CRS. All the laboratory assays were performed in a single-blinded manner.

Table 1. Subjects' characteristics

Characteristics	Control	CRSsNP	NP
Subjects (no.)	13	12	29
Sex (M/F)	8/5	9/3	19/10
Age (y)	45 (28-62)	42 (26-60)	52 (31-74)
Duration (y)	—	5 (3-9)	7 (2-12)
Asthma history, yes/no	—	1/11	3/26
AERD history	—	—	—
Smoking history, yes/no	—	3/9	8/21
Skin prick test response, positive/negative	—	2/10	9/20

CRSsNP, chronic rhinosinusitis without nasal polyps; NP, nasal polyps; AERD, Aspirin-exacerbated respiratory disease; M, male; F, female.

Each specimen was divided into 3 pieces for further analysis. The first was stored immediately in RNA-stabilizing solution (RNAlater; Tiangen, Beijing, China) for subsequent RNA extraction; the second was fixed with 4% paraformaldehyde and then embedded in paraffin wax for immunohistochemical (IHC) staining; and the third was stored immediately at -80°C for western blot analysis. In addition, the correlation between GPR17 and CysLR1R levels in polyp tissues was evaluated.

qRT-PCR

The mRNA expression levels of GPR17 and CysLT1R were evaluated using quantitative real-time polymerase chain reaction (qRT-PCR) analysis as previously described.¹⁴ Briefly, total RNA was extracted with TRIzol reagent (Invitrogen, Carlsbad, CA), according to the manufacturer's instructions. Reverse transcription was performed, in which cDNA for quantitative PCR was synthesized from 2 µg of total RNA using an oligo (dT) 18 primer and M-MLV reverse transcriptase (Takara, Dalian, China). RNA integrity and the success of the reverse transcription reaction were monitored by PCR amplification of β-actin transcripts. Messenger RNA (mRNA)

expression was determined using the ABI PRISM 7500 Detection System (Applied Biosystems, Foster City, CA) with SYBR Premix Taq (Takara, Dalian, China). The primer sequences were as follows: GPR17 forward, 5'-CCC TGG CTC TGT GGC TTT TC-3'; GPR17 reverse, 5'-TCT CGT TGG TTT TCC CTT CG-3'; CysLT1R forward, 5'-ACT TCC GCA ATC AAG TGT ATT-3'; CysLT1R reverse, 5'-ATT GCC AAA GAA GCC TAC AAC-3'; β -actin forward, 5'-TGT GTT GGC GTA CAG GTC TTT G-3'; β -actin reverse, 5'-GGG AAA TCG TGC GTG ACA TTA AG-3'. The qRT-PCR amplification protocol consisted of 40 cycles of denaturation at 95°C for 15 seconds and annealing and extension cycles at 60°C for 45 seconds each. Melting curve analysis was used to control for amplification specificity. The mean cycle threshold (Ct) values were normalized to those of β -actin, and the relative mRNA levels of the target genes were analyzed using the $2^{-\Delta\Delta Ct}$ method. Experiments were performed in triplicate for each data point.

IHC staining

Immunohistochemical staining was performed using a peroxidase-labeled streptavidin-biotin technique as described.¹⁴ Briefly, paraffin-embedded human nasal tissues were cut into 4- μ m sections and placed onto glass slides. The sections were incubated overnight at 4°C with primary antibodies against GPR17 and CysLT1R with a dilution of 1:200 (Abcam, Cambridge, MA). Subsequently, each of the sections was incubated with a secondary antibody and then detected with streptavidin-biotin-horseradish peroxidase complex (Zhongshan-jinqiao, Beijing, China). Immunostaining was considered positive when brown cells were obtained after treatment with 3% 3,3'-diaminobenzidine reagent. Negative controls were performed by replacing the primary antibodies with normal IgG at appropriate concentrations. The sections were examined and scored by 2 independent observers who were blind to the diagnosis and clinical data. The numbers of positive cells were counted in 5 randomly selected HPFs ($\times 400$ magnification) and averaged.

Western blot analysis

GPR17 and CysLT1R protein levels were determined by western blot analysis. Briefly, the tissues were dissected on ice and homogenized by sonication in radioimmunoprecipitation assay (RIPA) lysis buffer containing a protease inhibitor cocktail (Sigma-Aldrich, St. Louis, MO). The protein concentration in the supernatants was determined using the BCA method. Samples containing 15 μ g of protein were boiled, subjected to SDS-PAGE in 10% Tris-glycine gels, and electrophoretically transferred to a polyvinylidene fluoride membrane. The membrane was blocked with 5% fat-free milk in Tris-buffered solution (TBS) containing 0.05% Tween-20 for 1 hour at room temperature before being incubated with primary antibodies against GPR17 and CysLT1R at a dilution of 1:2,000 (Abcam, Cambridge, MA) overnight at 4°C. The membrane was then washed and incubated with a horseradish peroxidase-linked secondary antibody before being processed with the enhanced chemiluminescence (ECL) reaction kit and exposed on medical film. The relative band density of the target protein relative to the β -actin protein was determined with Bio-Rad Quantity One 1-D Analysis Software (Bio-Rad Laboratories, Hercules, Calif).

Statistical analysis

Data were expressed as medians and interquartile ranges. These data were analyzed using the Kruskal-Wallis H test and the nonparametric Mann-Whitney U test. The correlation between GPR17 and CysLT1R expression levels in the same nasal polyps was assessed using the Spearman rank correlation test. A P value of less than 0.05 was considered statistically significant.

Results

GPR17 and CysLT1R mRNA levels in nasal tissues

To determine whether cysLT receptor molecules are altered in polyp tissues from patients with CRSwNP, we first determined the expression levels of GPR17 and CysLT1R in nasal tissues. As indicated by qRT-PCR (Figure 1A, B),

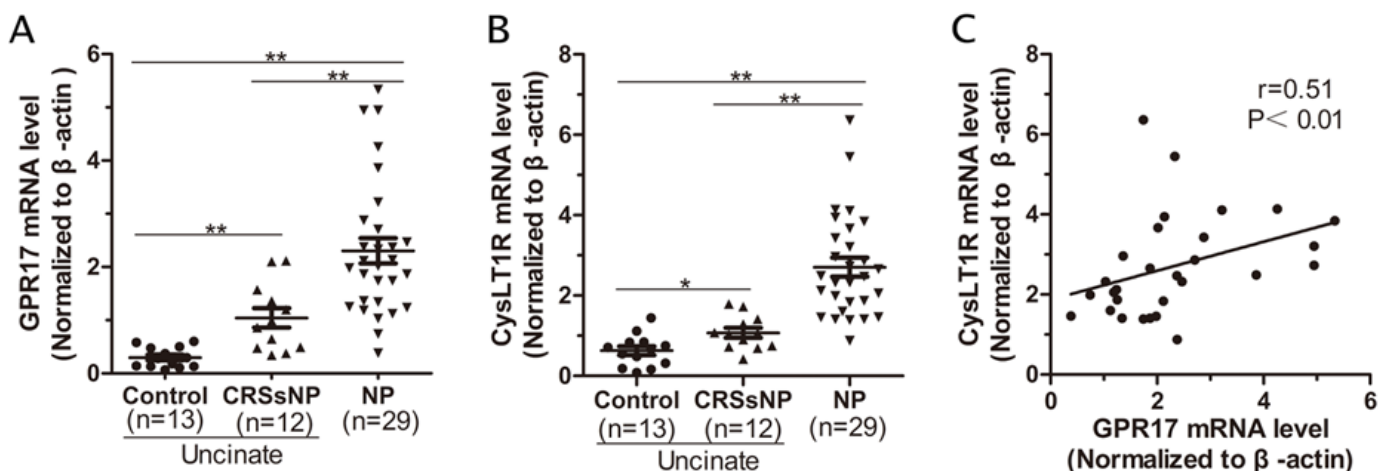


Figure 1. CysLT1R and GPR17 mRNA expression in nasal tissues. The GPR17 (A), and CysLT1R (B) mRNA levels were significantly increased in polyp tissues compared with the observed values seen in the other subgroups. (C), Correlation between the GPR17 and CysLT1R mRNA levels in the same NP tissues. The results are expressed as medians (interquartile ranges). CRSsNP, chronic rhinosinusitis without nasal polyps; NP, nasal polyp. *, $P<0.05$; and **, $P<0.01$.

the GPR17 and CysLT1R mRNA levels in polyp tissues from patients with CRSwNP were significantly higher than in unciate tissues from patients with CRSsNP or from control subjects ($P<0.01$). Interestingly, significant differences in GPR17 and CysLT1R mRNA expression were observed between unciate tissues from patients with CRSsNP and healthy controls (Figure 1A, B). Additionally, there was a positive correlation between the mRNA levels of GPR17 and CysLT1R in nasal polyps (Figure 1C; $r=0.51$, $P<0.01$).

GPR17 and CysLT1R immunoreactivity in nasal tissues

As indicated by IHC (Figure 2A), GPR17 and CysLT1R exhibited strong cytoplasmic staining that was mainly located in the inflammatory cells in the lamina propria of polyp tissues. In contrast, we found that GPR17 and CysLT1R

immunoreactivity was quite weak in normal tissues. The mean number of GPR17- and CysLT1R-positive cells was significantly increased in nasal polyps from patients with CRSwNP relative to unciate tissues from patients with CRSsNP or from control subjects (Figure 2B, C). Furthermore, the numbers of GPR17+ cells and CysLT1R+ cells in the polyp tissues were positively correlated (Figure 2D; $r=0.44$, $P<0.05$).

GPR17 and CysLT1R protein levels in nasal tissues

Using western blot analysis (Figure 3A-C), we found that the GPR17 and CysLT1R protein levels were significantly increased in polyp tissues from patients with CRSwNP relative to unciate tissues from patients with CRSsNP or from healthy controls ($P<0.01$). Furthermore, we found a positive correlation between protein levels of GPR17 and CysLT1R in nasal polyps (Figure 3D; $r=0.49$, $P<0.01$).

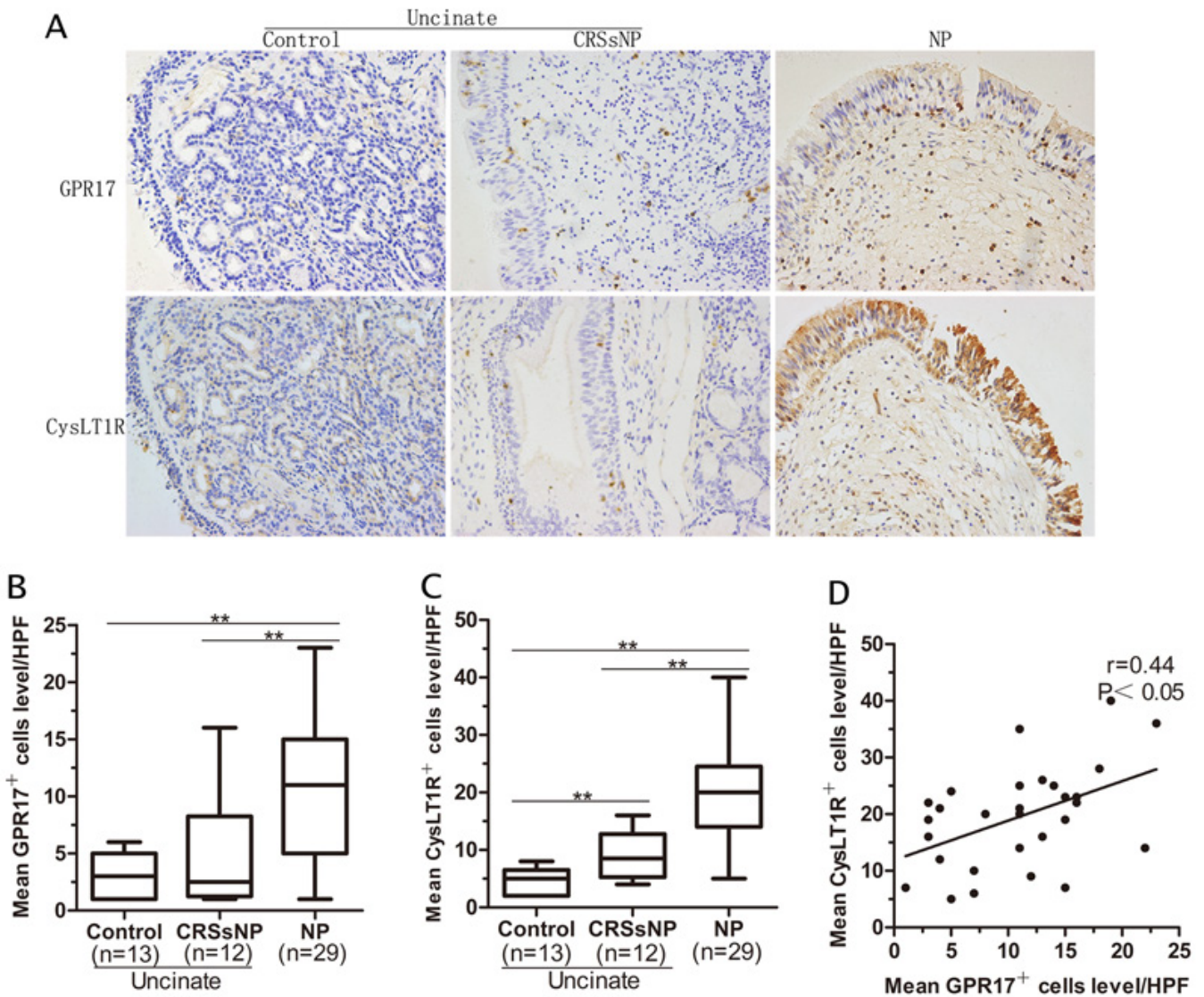
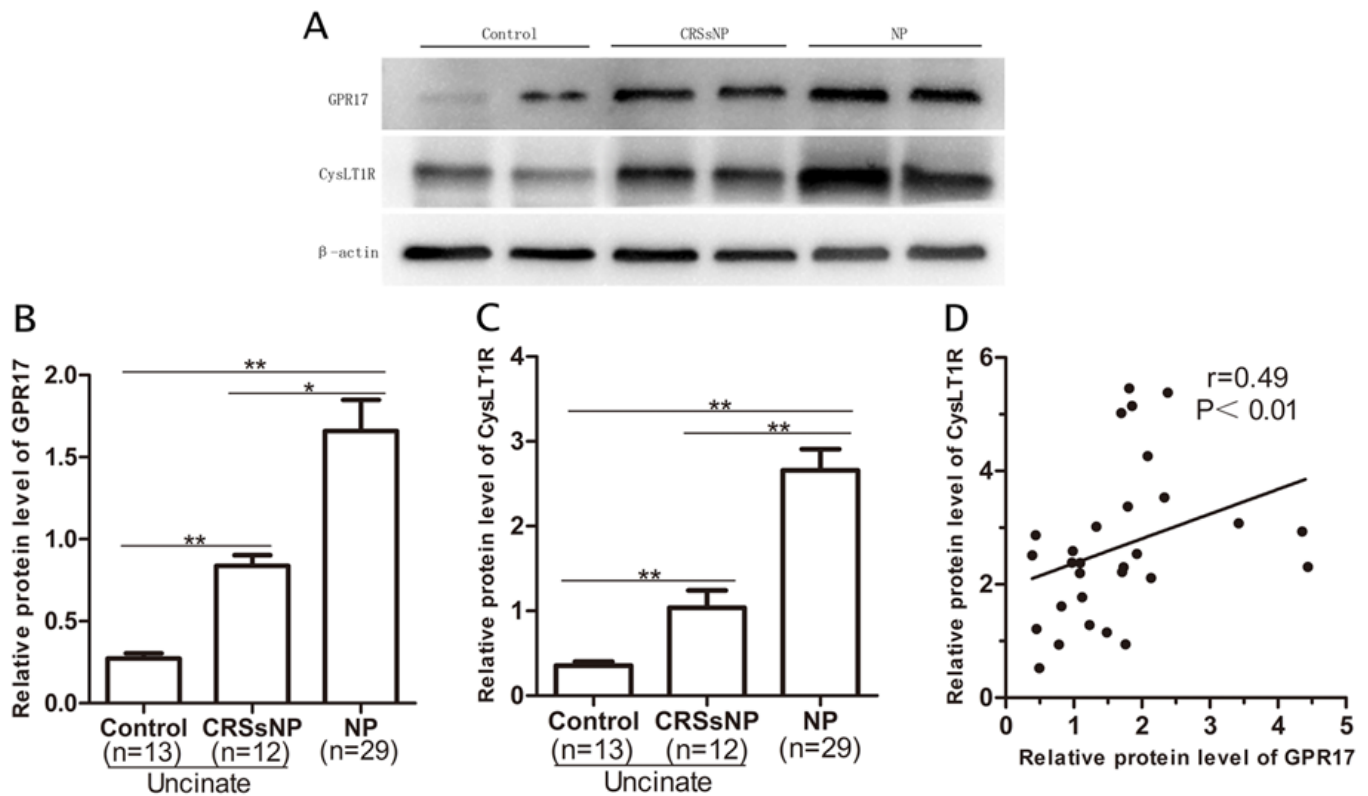


Figure 2. Immunoreactivity of CysLT1R and GPR17 in nasal tissues. (A) Representative IHC staining of GPR17 and CysLT1R in the 3 subgroups (magnification, $\times 200$). (B, C) Quantitative analysis of GPR17+ cells and CysLT1R+ cells in healthy controls, CRSsNP patients, and NP patients. (D) Correlation between GPR17+ and CysLT1R+ cells counts in the same polyp tissues. The data are expressed as medians (interquartile ranges). IHC, immunohistochemistry; HPE, high-power field; CRSsNP, chronic rhinosinusitis without nasal polyps; NP, nasal polyp. **, $P<0.01$.



GPR17 and CysLT1R are differentially expressed in the eosinophilic and non-eosinophilic CRSwNP subsets

When comparing the GPR17 and CysLT1R mRNA levels between the 2 CRSwNP subsets, we found that the mRNA levels were significantly higher in the ECRS patient subset than that in the non-ECRS subset (Figure 4A, B; $P < 0.01$).

Furthermore, we found that the mean number of GPR17- and CysLT1R-positive cells was significantly greater in ECRS patients than in non-ECRS patients (Figure 4C-E; $P < 0.05$). The GPR17 and CysLT1R protein levels were also clearly elevated in polyp tissues from patients with ECRS relative to those in non-ECRS patients (Figure 5A-C; $P < 0.01$).

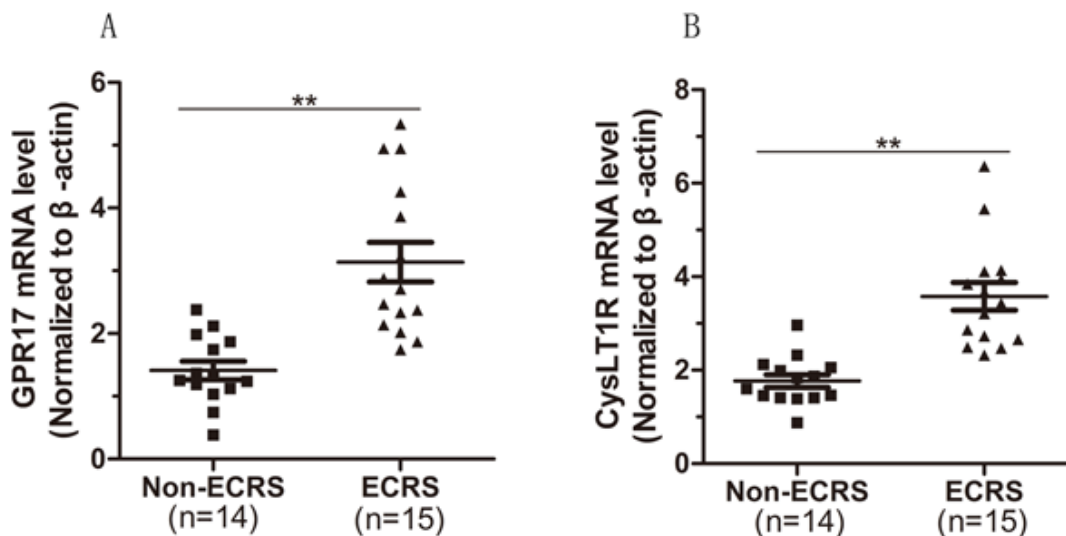


Figure 4. mRNA expression and distribution of GPR17 and CysLT1R in eosinophilic and noneosinophilic polyp tissues. (A, B) mRNA expression of CysLT1R and GPR17 in polyp tissues.

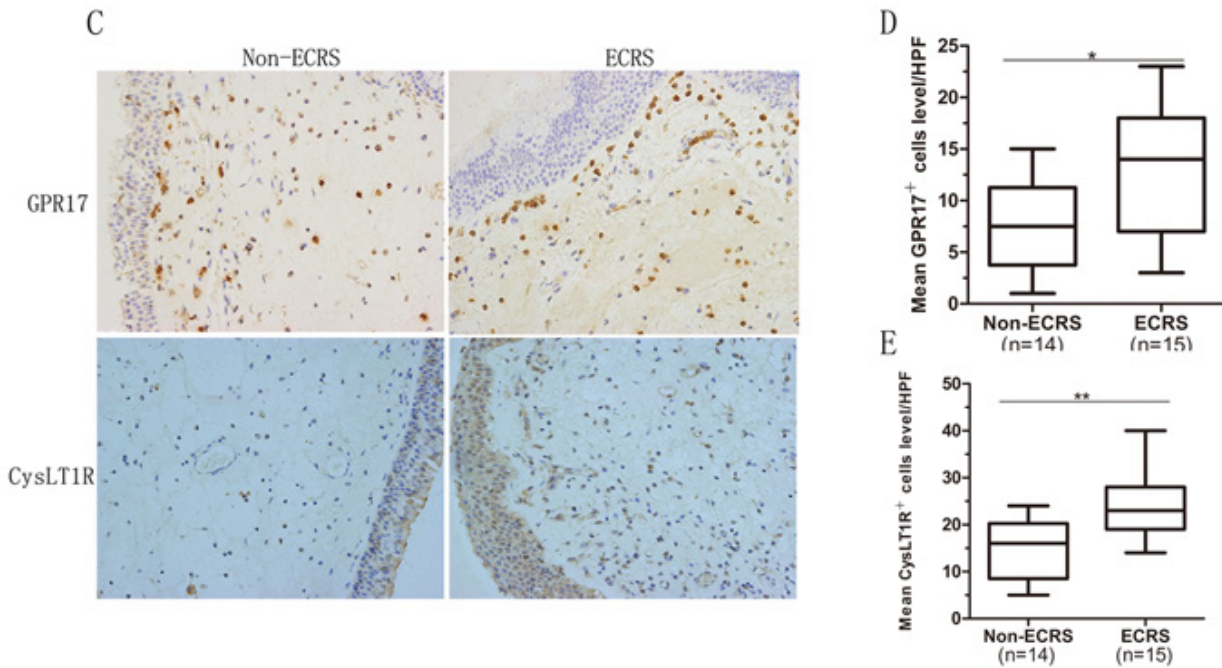


Figure 4. (Continued) (C) Representative GPR17 and CysLT1R staining ($\times 200$) in nasal tissues from patients with ECRS, patients with non-ECRS, and control subjects. (D, E) Quantitative analysis of GPR17⁺ and CysLT1R⁺ cells in patients with ECRS and non-ECRS. The data are expressed as medians (interquartile ranges). HPF, high-power field; ECRS, eosinophilic chronic rhinosinusitis with nasal polyp; non-ECRS, noneosinophilic chronic rhinosinusitis with nasal polyp. *, $P < 0.05$; **, $P < 0.01$.

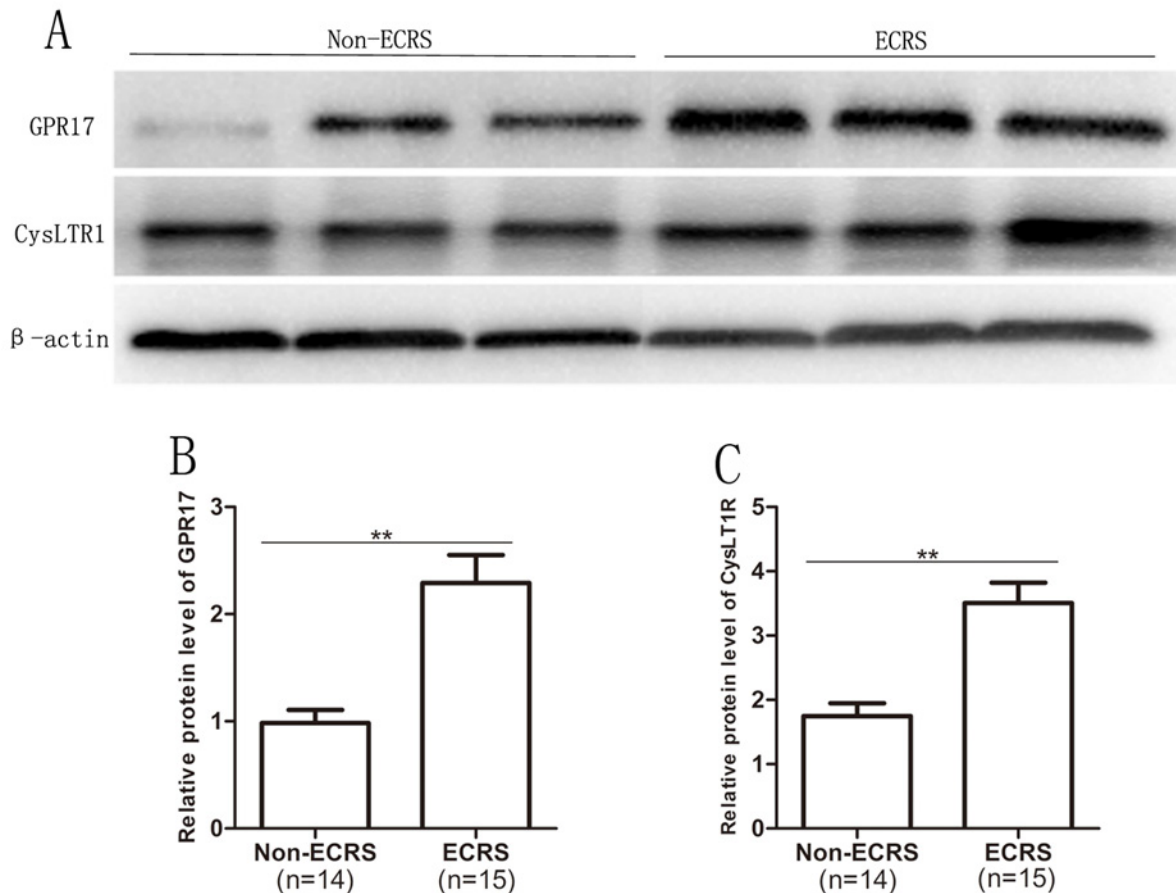


Figure 5. Protein levels of GPR17 and CysLT1R in eosinophilic and noneosinophilic polyp tissues. (A) Representative western blot analysis of GPR17 and CysLT1R in the ECRS and non-ECRS groups. (B, C) Quantitative analysis of GPR17 and CysLT1R protein levels in non-ECRS patients and ECRS patients. The data are expressed as medians (interquartile ranges). ECRS, eosinophilic chronic rhinosinusitis with nasal polyp; non-ECRS, noneosinophilic chronic rhinosinusitis with nasal polyp. **, $P < 0.01$.

Discussion

CRSwNP is traditionally considered a chronic inflammatory disease of the upper airways, with an enhanced Th2 response, eosinophilic inflammation, and massive edema. The endotyping patients of CRSwNP patients by histopathological classification (eosinophilic vs. non-eosinophilic) rather than by simple clinical phenotypes (CRSwNP vs. CRSsNP) reflects a change in the understanding the underlying inflammatory processes in order to design more-effective approaches to disease management.³ On the basis of such immunopathogenic findings, corticosteroids have been accepted as a central element in treatment strategies and have proven to be quite effective for CRSwNP patients. Corticosteroids show a potent anti-inflammatory function by suppressing the gene transcription of proinflammatory products and reducing airway inflammatory cell infiltration and function. Compared with a placebo, corticosteroids have improved overall symptom scores, reduced polyp sizes, decreased polyp scores, and prevented polyp recurrence after sinus surgery.^{15,16} Nevertheless, even with corticosteroid therapy and surgical intervention, more than 10% of severe CRSwNP patients show corticosteroid resistance.¹⁷

There has been much research into the immunologic basis of CRSwNP with the aim of identifying more targeted pharmacologic therapies. Recent studies have shown increased levels of cysLTs and their receptors localized to nasal polyps.^{18,19} CysLTs bind to G-protein-coupled receptors to promote localized inflammation, including eosinophil infiltration, mucus production, collagen deposition, and the release of mast cell cytokines.²⁰ Theoretically, patients with CRSwNP and concomitant asthma or atopy are more responsive to treatment with leukotriene receptor antagonists (LTRAs). This idea is supported by the reduced polyp size and decreased number of systemic eosinophils after montelukast treatment, as eosinophil levels are closely linked to disease severity, CRSwNP, asthma, and allergies.^{21,22}

To the best of our knowledge, the expression of GPR17 in the human nasal mucosa has not been previously addressed. In this study, we examined the expression of GPR17 and CysLT1R in nasal tissues. We found that GPR17 and CysLT1R levels were significantly elevated in nasal polyps relative to uncinate tissues from patients with CRSsNP or from control subjects. Next, we analyzed the relationship between GPR17 and CysLT1R levels in nasal polyps. Interestingly, we found a positive association between GPR17 and CysLT1R at both the mRNA and protein levels. Additionally, our previous data and those from other studies have shown that enhanced CysLT1R expression in polyp tissues may play a critical role in the pathogenesis of nasal polyps.^{13,18} As GPR17 and CysLT1R are homologous cysLT receptors that are phylogenetically related,^{6,7} we speculated that GPR17 and CysLT1R might have somewhat regulatory mechanisms in the pathogenesis of polyp tissues.

Patients with ECRS show a strong possibility of having overlapping mechanisms that cause eosinophilia, and they typically respond poorly to medical management. Accordingly, ECRS is considered a refractory and intractable disease.²³ In the present study, we specifically enrolled an uncontrolled ECRS subpopulation and evaluated GPR17 and CysLT1R levels in polyp tissues. We found a significant difference in the

expression of GPR17 and CysLT1R between ECRS and non-ECRS patients. The up-regulated GPR17 and CysLT1R expression in the ECRS subgroup was consistent with our previous report that CysLT1R expression is associated with tissue eosinophilia in CRSwNP patients.¹³ In summary, the different GPR17 expression in patients with eosinophilic and non-eosinophilic CRSwNP potentially reflects different pathogenic mechanisms underlying the development of nasal polyps. The findings reported here may contribute to a better understanding of the pathogenic processes involved in these 2 CRSwNP subsets and may aid in designing novel therapeutic strategies that target GPR17 to improve the clinical outcomes of CRSwNP patients.

Conclusion

In summary, our findings indicate that GPR17 and CysLT1R expression is significantly up-regulated in nasal polyps. In addition, we found differential expression of GPR17 between the eosinophilic and non-eosinophilic CRSwNP subsets, which may suggest the existence of distinct pathogenic mechanisms. The correlation between GPR17 and CysLT1R in polyp tissues implies a common regulatory mechanism. The detail of such mechanism remains to be elucidated.

Acknowledgements

This study was supported by the National Natural Science Fund of China under Grant 81470673.

Conflict of interest

The authors report no conflicts of interest. The authors alone are responsible for the content and writing of the paper.

Funding sources for the study

This study was supported by the National Natural Science Fund of China under Grant 81470673.

Authors' contributions

Li and Yang designed the study and wrote the manuscript. Chen supported the writing of the manuscript and the data analysis. Yu participated in the data analysis.

Disclosure statement

The authors report no conflicts of interest. The authors alone are responsible for the content and writing of the paper.

References

1. Fokkens WJ, Lund VJ, Mullol J, Bachert C, Alobid L, Baroody F, et al. EPOS 2012: European position paper on rhinosinusitis and nasal polyps 2012. A summary for otorhinolaryngologists. *Rhinology*. 2012; 50:1-12.
2. Hsu J, Peters AT. Pathophysiology of chronic rhinosinusitis with nasal polyp. *Am J Rhinol Allergy*. 2011; 25:285-90.
3. Akdis CA, Bachert C, Cingi C, Dykewicz MS, Hellings PW, Naclerio RM, et al. Endotypes and phenotypes of chronic rhinosinusitis: A PRACTALL document of the European Academy of Allergy and Clinical Immunology and the American Academy of Allergy, Asthma Immunology. *J Allergy Clin Immunol*. 2013;131:1479-90.
4. Payne SC, Borish L, Steinke JW. Genetics and phenotyping in chronic sinusitis. *J Allergy Clin Immunol*. 2011;128:710-20.

5. Chin D, Harvey RJ. Nasal polyposis: an inflammatory condition requiring effective anti-inflammatory treatment. *Curr Opin Otolaryngol Head Neck Surg.* 2013;21:23-30.
 6. Jacobson KA, Boeynaems JM. P2Y nucleotide receptors: promise of therapeutic applications. *Drug Discov Today.* 2010;15:570-8.
 7. Ciana P, Fumagalli M, Trincavelli ML, Verderio C, Rosa P, Lecca D, et al. The orphan receptor GPR17 identified as a new dual uracil nucleotides/cysteinyl-leukotrienes receptor. *EMBO J.* 2006;25:4615-27.
 8. Lynch KR, O'Neill GP, Liu Q, Im DS, Sawyer N, Metters KM, et al. Characterization of the human cysteinyl leukotriene CysLT1 receptor. *Nature.* 1999;399:789-93.
 9. Saad MA, Abdelsalam RM, Kenawy SA, Attia AS. Montelukast, a cysteinyl leukotriene receptor-1 antagonist protects against hippocampal injury induced by transient global cerebral ischemia and reperfusion in rats. *Neurochem Res.* 2015;40:139-50.
 10. Maekawa A, Xing W, Austen KF, Kanaoka Y. GPR17 regulates immune pulmonary inflammation induced by house dust mites. *J Immunol.* 2010;185:1846-54.
 11. Choi JH, Kim MA, Park HS. An update on the pathogenesis of the upper airways in aspirin-exacerbated respiratory disease. *Curr Opin Allergy Clin Immunol.* 2014;14:1-6.
 12. Steinke JW, Bradley D, Arango P, Crouse CD, Frierson H, Kountakis SE, et al. Cysteinyl leukotriene expression in chronic hyperplastic sinusitis-nasal polyposis: importance to eosinophilia and asthma. *J Allergy Clin Immunol.* 2003;111:342-9.
 13. Wu X, Hong H, Zuo K, Han M, Li J, Wen W, et al. Expression of leukotriene and its receptors in eosinophilic chronic rhinosinusitis with nasal polyps. *Int Forum Allergy Rhinol.* 2016;6:75-81.
 14. Wen W, Liu W, Zhang L, Bai J, Fan Y, Xia W, et al. Increased neutrophilia in nasal polyps reduces the response to oral corticosteroid therapy. *J Allergy Clin Immunol.* 2012;129:1522-8.
 15. Mullol J, Obando A, Pujols L, Alobid I. Corticosteroid treatment in chronic rhinosinusitis: the possibilities and limits. *Immunol Allergy Clin North Am.* 2009;29:657-68.
 16. Nonaka M, Tanaka Y, Pawankar R, Yoshihara T. Orally inhaled fluticasone propionate improved chronic rhinosinusitis with co-asthma: report of a case. *Asian Pac J Allergy Immunol.* 2013;31(1):84-87.
 17. Hellings PW, Fokkens WJ, Akdis C, Bachert C, Cingi C, Dietz de Loos D, et al. Uncontrolled allergic rhinitis and chronic rhinosinusitis: where do we stand today? *Allergy.* 2013;68:1-7.
 18. Chao SS, Graham SM, Brown CL, Kline JN, Hussain I. Cysteinyl leukotriene 1 receptor expression in nasal polyps. *Ann Otol.* 2006;115:394-7.
 19. Schäper C, Noga O, Koch B, Ewert R, Felix SB, Gläser S, et al. Anti-inflammatory properties of montelukast, a leukotriene receptor antagonist in patients with asthma and nasal polyposis. *J Investig Allergol Clin Immunol.* 2011;21:51-8.
 20. Holgate ST, Peters-Golden M, Panettieri RA, Henderson WR Jr. Roles of cysteinyl leukotrienes in airway inflammation, smooth muscle function, and remodeling. *J Allergy Clin Immunol.* 2003;111:S18-34.
 21. Schmid C, Habermann W, Braun H, Gugatschka M, Oriol BS, Smietana JA, et al. Released intranasal eosinophilic major basic protein as a diagnostic for polypoid chronic rhinosinusitis. *Otolaryngol Head Neck Surg.* 2010;143:386-91.
 22. Ahmadiafshar A, Taghiloo D, Esmailzadeh A, Falakaflaki B. Nasal eosinophilia as a marker for allergic rhinitis: a controlled study of 50 patients. *Ear Nose Throat J.* 2012;91:122-4.
 23. Ishinaga H, Shah SA, Sakaida H, Takeuchi K. The role of transforming growth factor- α on mucin overproduction in eosinophilic chronic rhinosinusitis. *Pharmacology.* 2011;88:302-8.
-